




Contents lists available at ScienceDirect

Clinical Microbiology and Infection

journal homepage: www.clinicalmicrobiologyandinfection.com

Original article

Diagnosis and management of *Aspergillus* diseases: executive summary of the 2017 ESCMID-ECMM-ERS guideline

A.J. Ullmann^{1, 62, 63}, J.M. Aguado^{2, 62, 63}, S. Arikan-Akdagli^{3, 62, 63}, D.W. Denning^{4, 5, 6, 63}, A.H. Groll^{7, 62, 63}, K. Lagrou^{8, 62, 63}, C. Lass-Flörl^{9, 62, 63}, R.E. Lewis^{10, 62}, P. Munoz^{11, 12, 13, 62, 63}, P.E. Verweij^{14, 62, 63}, A. Warris^{15, 62, 63}, F. Ader^{16, 17, 65}, M. Akova^{18, 62, 63}, M.C. Arendrup^{19, 62, 63}, R.A. Barnes^{20, 63}, C. Beigelman-Aubry^{21, 65}, S. Blot^{22, 23, 65}, E. Bouza^{11, 12, 13, 62, 63}, R.J.M. Brüggemann^{24, 62}, D. Buchheidt^{25, 62, 63}, J. Cadranel^{26, 65}, E. Castagnola^{27, 62}, A. Chakrabarti^{28, 63}, M. Cuenca-Estrella^{29, 62, 63}, G. Dimopoulos^{30, 65}, J. Fortun^{31, 62, 63}, J.-P. Gangneux^{32, 62, 63}, J. Garbino^{33, 62, 63}, W.J. Heinz^{1, 62, 63}, R. Herbrecht^{34, 62}, C.P. Heussel^{35, 63}, C.C. Kibbler^{36, 63}, N. Klimko^{37, 63}, B.J. Kullberg^{24, 62, 63}, C. Lange^{38, 39, 40, 65}, T. Lehrnbecher^{41, 63}, J. Löffler^{1, 62, 63}, O. Lortholary^{42, 62, 63}, J. Maertens^{43, 62, 63}, O. Marchetti^{44, 45, 62, 63}, J.F. Meis^{46, 62, 63}, L. Pagano^{47, 63}, P. Ribaud⁴⁸, M. Richardson^{4, 5, 6, 62, 63}, E. Roilides^{49, 50, 62, 63}, M. Ruhnke^{51, 62, 63}, M. Sanguinetti^{52, 62, 63}, D.C. Sheppard^{53, 62, 63}, J. Sinkó^{54, 62}, A. Skiada^{55, 62, 63}, M.J.G.T. Vehreschild^{56, 57, 58, 63}, C. Viscoli^{59, 62, 63}, O.A. Cornely^{56, 58, 60, 61, 62, 63, 64, *}



Download Clinical Guidelines

- ¹ Department of Infectious Diseases, Haematology and Oncology, University Hospital Würzburg, Würzburg, Germany
² Infectious Diseases Unit, University Hospital Madrid, Madrid, Spain
³ Department of Medical Microbiology, Hacettepe University Medical School, Ankara, Turkey
⁴ The National Aspergillosis Centre, Wythenshawe Hospital, Mycology Reference Centre Manchester, Manchester University NHS Foundation Trust, ECMM Excellence Centre of Medical Mycology, Manchester, UK
⁵ The University of Manchester, Manchester, UK
⁶ Manchester Academic Health Science Centre, Manchester, UK
⁷ Department of Paediatric Haematology/Oncology, Centre for Bone Marrow Transplantation, University Children's Hospital Münster, Münster, Germany
⁸ Department of Microbiology and Immunology, ECMM Excellence Centre of Medical Mycology, University Hospital Leuven, Leuven, Belgium
⁹ Institute of Hygiene, Microbiology and Social Medicine, ECMM Excellence Centre of Medical Mycology, Medical University Innsbruck, Innsbruck, Austria
¹⁰ Infectious Diseases Clinic, Sant'Orsola-Malpighi Hospital, University of Bologna, Bologna, Italy
¹¹ Department of Medical Microbiology and Infectious Diseases, Hospital General Universitario Gregorio Marañón, Madrid, Spain
¹² CIBER Enfermedades Respiratorias - CIBERES (CB06/06/0058), Madrid, Spain
¹³ Medicine Department, School of Medicine, Universidad Complutense de Madrid, Madrid, Spain
¹⁴ Department of Medical Microbiology, Radboud University Medical Centre, Centre of Expertise in Mycology Radboudumc/CWZ, ECMM Excellence Centre of Medical Mycology, Nijmegen, Netherlands
¹⁵ MRC Centre for Medical Mycology, Institute of Medical Sciences, University of Aberdeen, Aberdeen, UK
¹⁶ Department of Infectious Diseases, Hospices Civils de Lyon, Lyon, France
¹⁷ Inserm 1111, French International Centre for Infectious Diseases Research (CIRI), Université Claude Bernard Lyon 1, Lyon, France
¹⁸ Department of Medicine, Section of Infectious Diseases, Hacettepe University Medical School, Ankara, Turkey
¹⁹ Department Microbiological Surveillance and Research, Statens Serum Institute, Copenhagen, Denmark
²⁰ Department of Medical Microbiology and Infectious Diseases, Institute of Infection and Immunity, School of Medicine, Cardiff University, Cardiff, UK
²¹ Department of Diagnostic and Interventional Radiology, Centre Hospitalier Universitaire Vaudois (CHUV), Lausanne, Switzerland
²² Department of Internal Medicine, Ghent University, Ghent, Belgium
²³ Burns, Trauma and Critical Care Research Centre, University of Queensland, Brisbane, Australia
²⁴ Radboud Centre for Infectious Diseases, Radboud University Medical Centre, Centre of Expertise in Mycology Radboudumc/CWZ, ECMM Excellence Centre of Medical Mycology, Nijmegen, Netherlands
²⁵ Medical Clinic III, University Hospital Mannheim, Mannheim, Germany
²⁶ Department of Pneumology, University Hospital of Tenon and Sorbonne, University of Paris, Paris, France
²⁷ Infectious Diseases Unit, Istituto Giannina Gaslini Children's Hospital, Genoa, Italy
²⁸ Department of Medical Microbiology, Postgraduate Institute of Medical Education & Research, Chandigarh, India
²⁹ Instituto de Salud Carlos III, Madrid, Spain

* Corresponding author. O.A. Cornely, FECCM, Department I for Internal Medicine, ECMM Excellence Centre of Medical Mycology, University Hospital, Kerpener Strasse 62, 50937 Cologne, Germany.

E-mail address: Oliver.cornely@uk-koeln.de (O.A. Cornely).

<https://doi.org/10.1016/j.cmi.2018.01.002>

1198-743X/© 2018 European Society of Clinical Microbiology and Infectious Diseases. Published by Elsevier Ltd. All rights reserved.

- ³⁰⁾ Department of Critical Care Medicine, Attikon University Hospital, National and Kapodistrian University of Athens, Medical School, Athens, Greece
- ³¹⁾ Infectious Diseases Service, Ramón y Cajal Hospital, Madrid, Spain
- ³²⁾ Univ Rennes, CHU Rennes, Inserm, Irset (Institut de Recherche en santé, environnement et travail) – UMR_S 1085, Rennes, France
- ³³⁾ Division of Infectious Diseases, University Hospital of Geneva, Geneva, Switzerland
- ³⁴⁾ Department of Haematology and Oncology, University Hospital of Strasbourg, Strasbourg, France
- ³⁵⁾ Diagnostic and Interventional Radiology, Thoracic Clinic, University Hospital Heidelberg, Heidelberg, Germany
- ³⁶⁾ Centre for Medical Microbiology, University College London, London, UK
- ³⁷⁾ Department of Clinical Mycology, Allergy and Immunology, North Western State Medical University, St Petersburg, Russia
- ³⁸⁾ International Health and Infectious Diseases, University of Lübeck, Lübeck, Germany
- ³⁹⁾ Clinical Infectious Diseases, Research Centre Borstel, Leibniz Center for Medicine & Biosciences, Borstel, Germany
- ⁴⁰⁾ German Centre for Infection Research (DZIF), Tuberculosis Unit, Hamburg-Lübeck-Borstel-Riems Site, Lübeck, Germany
- ⁴¹⁾ Division of Paediatric Haematology and Oncology, Hospital for Children and Adolescents, Johann Wolfgang Goethe-University, Frankfurt, Germany
- ⁴²⁾ Department of Infectious and Tropical Diseases, Children's Hospital, University of Paris, Paris, France
- ⁴³⁾ Department of Haematology, ECMM Excellence Centre of Medical Mycology, University Hospital Leuven, Leuven, Belgium
- ⁴⁴⁾ Infectious Diseases Service, Department of Medicine, Lausanne University Hospital, Lausanne, Switzerland
- ⁴⁵⁾ Department of Medicine, Ensemble Hospitalier de la Côte, Morges, Switzerland
- ⁴⁶⁾ Department of Medical Microbiology and Infectious Diseases, Canisius-Wilhelmina Hospital, Centre of Expertise in Mycology Radboudum/CWZ, ECMM Excellence Centre of Medical Mycology, Nijmegen, Netherlands
- ⁴⁷⁾ Department of Haematology, Università Cattolica del Sacro Cuore, Roma, Italy
- ⁴⁸⁾ Quality Unit, Pôle Prébloc, Saint-Louis and Lariboisière Hospital Group, Assistance Publique-Hôpitaux de Paris, Paris, France
- ⁴⁹⁾ Infectious Diseases Unit, 3rd Department of Paediatrics, Faculty of Medicine, Aristotle University School of Health Sciences, Thessaloniki, Greece
- ⁵⁰⁾ Hippokraton General Hospital, Thessaloniki, Greece
- ⁵¹⁾ Department of Haematology and Oncology, Paracelsus Hospital, Osnabrück, Germany
- ⁵²⁾ Institute of Microbiology, Fondazione Policlinico Universitario A. Gemelli – Università Cattolica del Sacro Cuore, Rome, Italy
- ⁵³⁾ Division of Infectious Diseases, Department of Medicine, Microbiology and Immunology, McGill University, Montreal, Canada
- ⁵⁴⁾ Department of Haematology and Stem Cell Transplantation, Szent István and Szent László Hospital, Budapest, Hungary
- ⁵⁵⁾ First Department of Medicine, Laiko Hospital, National and Kapodistrian University of Athens, Athens, Greece
- ⁵⁶⁾ Department I of Internal Medicine, ECMM Excellence Centre of Medical Mycology, University Hospital of Cologne, Cologne, Germany
- ⁵⁷⁾ Centre for Integrated Oncology, Cologne-Bonn, University of Cologne, Cologne, Germany
- ⁵⁸⁾ German Centre for Infection Research (DZIF) partner site Bonn-Cologne, Cologne, Germany
- ⁵⁹⁾ Ospedale Policlinico San Martino and University of Genova (DISSAL), Genova, Italy
- ⁶⁰⁾ CECAD Cluster of Excellence, University of Cologne, Cologne, Germany
- ⁶¹⁾ Clinical Trials Center Cologne, University Hospital of Cologne, Cologne, Germany
- ⁶²⁾ ESCMID Fungal Infection Study Group (EFISG)
- ⁶³⁾ European Confederation of Medical Mycology (ECMM)
- ⁶⁴⁾ ESCMID European Study Group for Infections in Compromised Hosts (ESGICH)
- ⁶⁵⁾ European Respiratory Society (ERS)

ARTICLE INFO

Article history:

Received 29 September 2017

Received in revised form

2 January 2018

Accepted 3 January 2018

Available online xxx

Editor: L. Leibovici

Keywords:

Aspergillosis

Diagnosis

Haematology

Invasive fungal infection

Transplantation

Treatment

ABSTRACT

The European Society for Clinical Microbiology and Infectious Diseases, the European Confederation of Medical Mycology and the European Respiratory Society Joint Clinical Guidelines focus on diagnosis and management of aspergillosis. Of the numerous recommendations, a few are summarized here. Chest computed tomography as well as bronchoscopy with bronchoalveolar lavage (BAL) in patients with suspicion of pulmonary invasive aspergillosis (IA) are strongly recommended. For diagnosis, direct microscopy, preferably using optical brighteners, histopathology and culture are strongly recommended. Serum and BAL galactomannan measures are recommended as markers for the diagnosis of IA. PCR should be considered in conjunction with other diagnostic tests. Pathogen identification to species complex level is strongly recommended for all clinically relevant *Aspergillus* isolates; antifungal susceptibility testing should be performed in patients with invasive disease in regions with resistance found in contemporary surveillance programmes. Isavuconazole and voriconazole are the preferred agents for first-line treatment of pulmonary IA, whereas liposomal amphotericin B is moderately supported. Combinations of antifungals as primary treatment options are not recommended. Therapeutic drug monitoring is strongly recommended for patients receiving posaconazole suspension or any form of voriconazole for IA treatment, and in refractory disease, where a personalized approach considering reversal of predisposing factors, switching drug class and surgical intervention is also strongly recommended. Primary prophylaxis with posaconazole is strongly recommended in patients with acute myelogenous leukaemia or myelodysplastic syndrome receiving induction chemotherapy. Secondary prophylaxis is strongly recommended in high-risk patients. We strongly recommend treatment duration based on clinical improvement, degree of immunosuppression and response on imaging. **A.J. Ullmann, *Clin Microbiol Infect* 2018;•:1**

© 2018 European Society of Clinical Microbiology and Infectious Diseases. Published by Elsevier Ltd. All rights reserved.

Introduction

This is the third fungal diagnosis and management clinical guideline published in cooperation with various European scientific societies [1–9]. This part of the guideline regarding invasive and chronic aspergillosis is a condensation of all the recommendations

made by the guideline subcommittees and is presented in tables for easier and faster reading. More details on how the recommendations were arrived at are planned in supplementary publications. This *Aspergillus* guideline will follow the style of other guidelines by including diagnostic and therapeutic guidance. Other scientific groups have published guidelines on this topic previously and all

follow the common goal to provide clinicians with best guidance in their everyday working environment. Our goal was to provide a comprehensive European guideline focusing on the life-threatening diseases caused by *Aspergillus* spp.

Methods

Author panel recruitment and organization was similar to what was done previously [10]. In brief, experts in the field were nominated by the three societies: European Society for Clinical Microbiology and Infectious Diseases (ESCMID), the European Confederation of Medical Mycology (ECMM) and the European Respiratory Society (ERS). The total of 53 authors were grouped into their special fields of expertise. Subgroup coordinators were responsible for the first draft of recommendations. There were two face-to-face meetings followed by numerous electronic exchanges. Some of the first recommendations were presented at ECCMID 2014. This summary was reviewed and approved by all authors and sent to the ESCMID guideline director for public review. Then the final version was submitted to *Clinical Microbiology and Infection* for additional peer review and subsequent publication. Only the rationale of the chronic pulmonary aspergillosis (CPA) guideline was published ahead of time [11].

Questions were predefined and modified where appropriate and the strength of recommendation and quality of evidence was slightly modified (Table 1) [12]. Diagnostic tests are regarded as interventions.

Summary of recommendations

Diagnostic procedures

Early diagnosis of invasive aspergillosis (IA) is a challenge and should be based on the integration of clinical, radiological and microbiological data.

Table 1
Strength of recommendation and quality of evidence

Strength of recommendation	Definition
Grade A	Societies <u>strongly</u> support a recommendation for use
Grade B	Societies <u>moderately</u> support a recommendation for use
Grade C	Societies <u>marginally</u> support a recommendation for use
Grade D	Societies support a recommendation <u>against</u> use
Quality of evidence	Definition
Level I	Evidence from at least one properly* designed randomized, controlled trial (oriented on the primary end point of the trial)
Level II	Evidence from at least one well-designed clinical trial (including secondary end points), without randomization; from cohort or case–controlled analytic studies (preferably from more than one centre); from multiple time series; or from dramatic results of uncontrolled experiments
Level III	Evidence from opinions of respected authorities, based on clinical experience, descriptive case studies, or reports of expert committees
Added index	Source of Level II evidence
r	Meta-analysis or systematic review of randomized controlled trials
t	Transferred evidence, i.e. results from different patients' cohorts, or similar immune-status situation
h	Comparator group: historical control
u	Uncontrolled trials
a	Published abstract presented at an international symposium or meeting

* Poor quality of planning, inconsistency of results, indirectness of evidence etc. would lower the Strength of recommendation.

Thoracic imaging

In patients at risk for IA with fever of unknown origin or clinical symptoms of lower respiratory tract infection who remain febrile despite broad-spectrum antibacterial treatment, thin-section chest computed tomography (multidetector (MDCT), multislice (MSCT), spiral CT, high resolution CT) at optimized dose (according to the ALARA ('As Low As Reasonably Achievable') principle) is the imaging modality of choice (**AI**) [13–23]. Pulmonary CT angiography may be of interest in the early diagnosis of IA by depicting directly vessel occlusion at the level of a suspicious fungal lesion with a potential high negative predictive value regarding imaging evaluation [24–26], and is required in case of haemoptysis (**AI**). In selected patients where CT is not wanted or not feasible, magnetic resonance imaging (MRI) of the lungs may represent an alternative imaging to thin-section MSCT [27–32], positron emission tomography-CT being of modest interest in the diagnostics of IA [33,34].

No CT scanning technique is 100% sensitive or specific for pulmonary IA [35–37]. Classical CT findings of angioinvasive aspergillosis include macronodule(s) >1 cm, which may be surrounded by a halo of ground-glass attenuation (halo sign, early phase, inconstant) [36,38–40], pleural based wedge-shaped areas of consolidation [41], alveolar consolidations [36,42,43], masses (especially in solid organ transplant (SOT) recipients) [15,38], internal low attenuation [44], reverse halo sign [45], cavity or air-crescent sign (delayed finding), ground glass opacities and pleural effusion [17,35,46]. Bronchoinvasive forms may appear as tracheal or bronchial wall thickening, centrilobular nodules with tree in bud appearance [14] in a patchy distribution, predominant peribronchial areas of consolidation [47] or bronchopneumonia [46] (Table 2).

Bronchoalveolar lavage and biopsies

Other diagnostic procedures include early bronchoalveolar lavage (BAL) (**AI**) [48–54], guided by CT findings [55,56], and less frequently CT-guided transthoracic biopsies, video-assisted thoracoscopic surgery, open lung biopsies, transbronchial biopsies or convex endobronchial ultrasound transbronchial needle aspiration, the latter technique appearing to be a promising procedure in this setting [28,57–72]. Contraindications to these techniques need to be considered.

Imaging of other sites

Moreover, according to clinical symptoms, paranasal CT, CT or MRI of the central nervous system (CNS) as well as abdominal CT may also be required. In particular, findings of sinusitis with bone erosion may be observed, intracranial and/or intraorbital extension of the disease being best evaluated by MRI [73–75]. In the brain, due to direct spread from paranasal sinuses or haematogenous dissemination, meningeal enhancement or empyema, cerebral abscess, mycotic aneurysms as well as haemorrhagic lesions and rarely stroke may be seen [76–79].

Microscopy and culture

Both microscopy and culture should be attempted on appropriate specimens from patients at risk for IA (**AI**) with a priority for culture in most cases where insufficient material is available. Demonstrating tissue invasion by hyphae through microscopic examination of biopsy or autopsy material provides a diagnosis of proven invasive fungal infection. However, the sensitivity of microscopy for IA is 50% at best [80]. Specimens may be examined as a wet mount preparation with or without the addition of 10%

Table 2
Recommendations for imaging and bronchoalveolar lavage

Population	Intention	Intervention ^a	SoR	QoE	Comment	Ref.
Neutropenia, fever or clinical symptoms of pneumonia, empiric antibiotics failing to achieve defervescence, e.g. FUO	To detect pulmonary infiltrates	Chest CT and thin section multi-detector CT (MDCT)	A	II	Dose optimization recommended	[21,31,35,366]
	To identify vessel occlusion	Chest angio-CT/pulmonary CT angiography	B	II		[24–26]
Haemoptysis	To identify vessel erosion	Chest angio-CT/pulmonary CT angiography	A	II		[367,368]
Any, with infiltrate	To identify possible underlying fungal or other infectious disease	BAL	A	II		[21,49–54]
Any, with infiltrate	To obtain appropriate specimens for microscopy, culture and PCR	CT-guided BAL	A	III		[55,56]

Abbreviations: BAL, bronchoalveolar lavage; CT, computed tomography; FUO, fever of unknown origin; PCR, polymerase chain reaction; QoE, Quality of evidence; SoR, Strength of recommendation.

^a Diagnostic tests are interventions.

potassium hydroxide. Fluorescent dyes such as Calcofluor White™ or Blancophor™ have the advantages of increased sensitivity, rapid turnaround time and broad applicability but are not specific for *Aspergillus* (AII). Gomori's methenamine silver stain (GMS) and periodic acid-Schiff (PAS) can be applied to histological sections and smears and should be conducted in all cases in which IA is considered a possibility (Table 3). Respiratory secretions from patients with suspected aspergillosis must be processed rapidly for culture to prevent overgrowth by bacteria and yeasts. To achieve optimal recovery of *Aspergillus* from BAL fluid, centrifugation of the sample is advised with investigation of the sediment (AIII). It is recommended that cultures of high volume untreated sputum and BAL should be performed as opposed to culturing small volumes of digested, liquefied samples [81] (Table 4). Specific media to support fungal growth are recommended. Species identification to the

complex level should be carried out for clinically relevant isolates from patients who need antifungal treatment, and for epidemiological purposes (AIII) (Table 5).

Non-culture based assays

Galactomannan (GM) detection in fluids (especially BAL) is more sensitive than culture for diagnosis of IA. GM is reported as optical density index (ODI). In serum samples an ODI cut-off of 0.5 results in high sensitivity in haematological patients in the absence of mould-active prophylaxis (AI) (Table 6). Serial screening for serum GM in prolonged neutropenia and in allogeneic stem cell transplantation recipients during the early engraftment phase has a high sensitivity and negative predictive value for IA (AII) [82]. Serial screening is not recommended in patients on mould-active prophylaxis [83].

Table 3
Microscopic examinations

Population	Intention	Intervention	SoR	QoE	Comment	Ref.
Any	To identify fungal elements in histological sections and stains	Histological examination Gomori's methenamine silver stain Periodic acid–Schiff	A	III	Histopathology is an essential investigation Inability to definitively distinguish other filamentous fungi GMS: removes cellular background; more sensitive to hyphal elements PAS: advantage of counter stain to check cellular detail	[61,80,369,370]
Any	To identify fungal elements in histological sections and stains	Fluorescent dyes: Calcofluor white™, Uvitex 2B, Blancophor™	A	II	Not specific to <i>Aspergillus</i> but high sensitivity and the micromorphology may provide information on the fungal class (e.g. <i>Aspergillus</i> : typically dichotomous and septate, Mucorales: pauci-septate and 90° angle branching, yeast: budding) Rapid turnaround time Broad applicability May be applied to frozen sections, paraffin-embedded tissue	[371–375]
Any	To identify fungal elements in histological sections and stains	Immunohistochemistry Monoclonal antibody WF-AF-1 or EB-A1 <i>In situ</i> hybridization	B	II	Have the potential to provide genus- and species-specific data Commercially available monoclonal antibodies WF-AF-1 is specific for <i>Aspergillus fumigatus</i> , <i>Aspergillus flavus</i> , and <i>Aspergillus niger</i> Time consuming and not broadly available	[371–375]
Any	To identify fungal elements in fresh clinical specimens (e.g. BAL)	Application of fluorescent dyes Calcofluor white™ or Uvitex 2B or Blancophor™	A	II	Essential investigation Not specific for <i>Aspergillus</i> species High sensitivity Rapid turn-around time Broad applicability No species identification but the micromorphology may provide information on the fungal class (e.g. <i>Aspergillus</i> : typically dichotomous and septate, Mucorales: pauci-septate and 90° angle branching, yeast: budding)	[61,80,376]

Abbreviations: BAL, bronchoalveolar lavage; CNS, central nervous system; GMS, Gomori's methenamine silver stain; HE, haematoxylin-eosin; PAS, Periodic acid–Schiff; QoE, Quality of evidence; SoR, Strength of recommendation.

Table 4
Sample selection and pre-analytical respiratory sample treatment

Population	Intention	Intervention	SoR	QoE	Comment	Ref.
Any	To achieve a homogeneous sample of viscous samples such as sputum	Liquefaction using a mucolytic agent, e.g. Pancreatin®, Sputolysin®, or using sonication and 1,4-dithiothreitol	A	III	Essential investigation High-volume sputum culture (entire sample) shown to significantly increase recovery	[81,377]
Any	To achieve optimal recovery of <i>Aspergillus</i> from BAL by centrifugation and investigation of the sediment	Centrifugation of BALs or bronchial aspirates	A	III	Essential investigation Isolation of <i>Aspergillus</i> dependent on volume cultured	[81]

Abbreviations: BAL, bronchoalveolar lavage; PCR, polymerase chain reaction; QoE, Quality of evidence; SoR, Strength of recommendation.

Table 5
Culture and *Aspergillus* species identification

Population	Intention	Intervention	SoR	QoE	Comment	Ref.
Any	Primary isolation from deep sites samples (e.g. biopsies, blood, CSF)	Culture on SDA, BHI agar, PDA at 30°C and 37°C for 72 h	A	III	Blood inhibits conidiation; BHI can help to recover some isolates; isolation of several colonies or isolation of the same fungus from a repeat specimen enhance significance	[81,378,379]
	Primary isolation from non-sterile samples, e.g. sputum, respiratory aspirates	Culture on SDA, BHI agar, PDA with gentamicin plus chloramphenicol at 30°C and 37°C for 72 h	A	III	High-volume sputum culture (entire sample) shown to significantly increase recovery; quantitative cultures are not discriminative for infection or colonization	
	Identification of species complex	Macroscopic and microscopic examination from primary cultures	A	II	Colony colour, conidium size, shape and septation. Colour of conidia and conidiophore and conidiogenesis (tease or tape mounts are preferred); expertise needed for interpretation	
	Identification of species complex (and species identification of <i>A. fumigatus</i> specifically)	Culture on identification media at 25–30°C, 37°C and 50°C (2% MEA and Czapek-Dox Agar) and microscopic examination	A	II	Thermotolerance test (growth at 50°C for species confirmation of <i>A. fumigatus</i>)	
	Identification at species level	MALDI-TOF MS identification	B	II	In-house databases are often used to improve identification rates	[380–383]
	Identification at species level	Sequencing of ITS, β -tubulin and calmodulin	A	III	Not necessary in organisms with typical growth, but in cases of atypical growth	[384,385]
	To study outbreaks	Microsatellite and CSP analysis	C	II	To study outbreaks (which in general may comprise more than one genotype)	[386–388]
			B	II	To study colonization patterns	[389]

Abbreviations: BHI, brain–heart infusion; CSF, cerebrospinal fluid; CSP, cell surface protein; ITS, internal transcribed spacer; MALDI-TOF MS, matrix-assisted laser desorption/ionization time-of-flight mass spectrometry identification; MEA, malt extract agar; PDA, potato dextrose agar; QoE, Quality of evidence; SDA, Sabouraud dextrose agar; SoR, Strength of recommendation.

Table 6
Galactomannan testing in blood samples

Population	Intention	Intervention	SoR	QoE	Comment	Ref.
Patients with prolonged neutropenia or allogeneic stem cell transplantation recipients not on mould-active prophylaxis	Prospective screening for IA	GM in blood ^a Draw samples every 3–4 days	A	I	Highest test accuracy requiring two consecutive samples with an ODI ≥ 0.5 or retesting the same sample Prospective monitoring should be combined with HRCT and clinical evaluation	[82,94,390–394]
			C	III		
Patients with prolonged neutropenic or allogeneic stem cell transplantation recipients on mould active prophylaxis	Prospective screening for IA	GM in blood ^a	D	II	Low prevalence of IA in this setting with consequently low PPV of blood GM test Prophylaxis may have a negative impact on sensitivity of the test or the low yield may be due to decreased incidence of IA	[395,396]
Patients with a haematological malignancy • Neutropenic patients • Non-neutropenic patients	To diagnose IA	GM in blood ^a	A	II	Significantly lower sensitivity in non-neutropenic patients	[319,391,397,398]
			B	II		
ICU patients	To diagnose IA	GM in blood ^a	C	II	Better performance in neutropenic than in non-neutropenic patients	[89,399]
Solid organ recipients	To diagnose IA	GM in blood ^a	C	II	Low sensitivity, good specificity Most data for lung SOT	[319,400,401]
Any other patient	To diagnose IA	GM in blood ^a	C	II	Piperacillin/tazobactam may no longer be responsible for false-positive results according to recent studies Cross-reactivity in case of histoplasmosis, fusariosis, talaromycosis (formerly: penicilliosis) False-positive results reported due to ingestion of ice-pops, transfusions, antibiotics, Plasmalyt® infusion	[398,402–409]
Cancer patients	To monitor treatment	GM in blood ^a	A	II		[85,353,410]

Abbreviations: GM, galactomannan; IA, invasive aspergillosis; ICU, intensive care unit; ODI, optical density index; PPV, positive predictive value; QoE, Quality of evidence; SoR, Strength of recommendation; SOT, solid organ transplantation.

^a Serum or plasma.

Table 7
Galactomannan testing in samples other than blood

Population	Intention	Intervention	SoR	QoE	Comment	Ref.
Any	To diagnose pulmonary IA	To apply GM test on BAL fluid	A	II	GM in BAL is a good tool to diagnose, optimal cut-off to positivity 0.5 to 1.0	[86,88,411–414]
Any	To diagnose cerebral IA	To apply GM test on cerebrospinal fluid	B	II	No validated cut-off	[415,416]
Any	To detect GM in tissue	To apply GM test on lung biopsies	B	II	Using a cut-off 0.5 resulted in a sensitivity of 90 % and a specificity of 95%; specimens need to be sliced, precondition for doing so is that sufficient material is available; dilution in isotonic saline	[61,417]

Abbreviations: BAL, bronchoalveolar lavage; GM, galactomannan; IA, invasive aspergillosis; QoE, Quality of evidence; SoR, Strength of recommendation.

Sensitivity of serum GM testing is significantly lower in non-neutropenic versus neutropenic patients [84]. Decrease of the ODI during the first 2 weeks of antifungal therapy is a reliable predictor of a satisfactory response in cancer patients [85]. GM detection in BAL specimens has an excellent performance with evidence that ODI of 0.5–1.0 has decreased predictive values compared with results of >1.0 [86] (AII) (Table 7). The test also has diagnostic value in patients undergoing lung transplantation or who are in intensive care [87–89]; a sensitivity of 100% and a specificity of 90.4% was defined at cut-off of 1.5 [87].

A constituent of the cell wall of many species and genera of fungi, (1-3)- β -D-glucan (BDG), is released into body fluids in association with fungal infection. A limited role is given for the exclusive testing of the BDG in diagnosing IA (BII) (Table 8); however, the combination with GM or PCR improves specific detection [90].

The *Aspergillus* lateral flow device assay can be performed on serum and on BAL samples, but at the time of writing this assay is not commercially available [91] (Table 9).

Aspergillus PCR has been applied mostly to blood and BAL fluid. For both sample types, a combination with other biomarkers increases the likelihood of IA [92,93]. The performance of serum PCR is not significantly different from that of whole blood [94–97]. Prospective screening of high-risk haematological patients by a combination of GM and PCR improves the diagnostic accuracy and is associated with an earlier diagnosis [98,99] (Tables 10 and 11).

Table 8
 β -D-glucan assays

Population	Intention	Intervention	SoR	QoE	Comment	Ref.
Mixed population: adult ICU, haematological disorders, SOT	To diagnose IFD	Diagnostic assay	C	II	Five different assays Overall sensitivity of 77% and specificity of 85% Specificity limits its value in this setting	[90,418]
		Screening assays	C	II	Two or more consecutive samples: sensitivity: 65%; specificity: 93% Studies included once to thrice weekly. Varies with assay and cut-off: Wako assay sensitivity: 40%–97%, specificity: 51%–99%	[90,418]
Adult haematological malignancy and HSCT	To diagnose IFD	Diagnostic assay	C	II	Overall sensitivity: 50%–70%, specificity: 91%–99%	[193–195,419–424]
ICU—mixed adult immunocompromised patients (haematology, SOT, cancer, immunosuppressive therapy, liver failure, HIV)	To diagnose IA	Diagnostic assay	C	II	Overall sensitivity: 78%–85%, specificity: 36%–75%, NPV: 85%–92% Specificity increased at higher cut-off values	[425,426]
		Screening assays	C	III	Sensitivity: 91%, specificity: 58%, PPV: 25%, NPV: 98%. Positive mean of 5.6 days before positive mould culture High false-positive rate in early ICU admission	[427]
Adult haematological malignancy and HSCT	To diagnose IA	Diagnostic assay	C	II	Overall sensitivity: 57%–76%, specificity: 95%–97%	[418,419,425]
		Screening assays	C	II	Overall sensitivity: 46%, specificity: 97% Confirmation with GM increases specificity Data suggest BDG is unsuitable for ruling out diagnosis of IA	

Abbreviations: BDG, β -D-glucan test; GM, galactomannan; HSCT, haematopoietic stem cell transplantation; IA, invasive aspergillosis; ICU, intensive care unit; IFD, invasive fungal disease; NPV, negative predictive value; PPV, positive predictive value; QoE, Quality of evidence; SoR, Strength of recommendation; SOT, solid organ transplantation.

On hyphal positive biopsy samples molecular detection of fungi is strongly recommended (AII). If no hyphae are visible the diagnostic yield of molecular methods is lower (Table 12). Recommendations for storage of original samples and isolates are given in Table 13. Antibody detection tests are not supported for the diagnosis of IA (CII) (Table 14).

Antifungal susceptibility testing

Resistance to antifungal agents is an increasing problem in *Aspergillus* diseases [100–102]. *Aspergillus* species can be intrinsically resistant to polyenes and azoles [103], or may acquire resistance following exposure to azole compounds [104]. Acquired resistance to azoles is mainly found in *Aspergillus fumigatus* and is reported globally [100,101,105–108]. Resistance may also develop through exposure to azole fungicides in the environment [109–112]. As resistant spores are present in ambient air, patients may present with azole-resistant *Aspergillus* disease without previous azole therapy [113,114]. Individual *Aspergillus* colonies from a single specimen may harbour different resistance profiles [117], hence multiple colony testing (up to five colonies) is recommended to increase sensitivity for azole-resistance detection (BIII).

In clinical laboratories, species identification to complex level is recommended for all clinically significant isolates (BIII). Some species are intrinsically resistant to either azoles or amphotericin B (Tables 5, 15–17).

Table 9
Lateral flow device antigen test for invasive aspergillosis

Population	Intention	Intervention	SoR	QoE	Comment	Ref.
Haematological malignancy and solid organ transplant	To diagnose IA	LFD applied on BAL samples	B	II	Retrospective study. Sensitivity and specificity of BAL LFD tests for probable IPA were 100% and 81% (PPV 71%, NPV 100%), five patients with possible IPA had positive LFD, no proven IA	[428]
Haematopoietic stem cell transplantation	To diagnose IA	LFD applied on serum samples	B	II	Prospective screening in 101 patients undergoing allogeneic HSCT	[429]
Immunocompromised patients	To diagnose IA	LFD applied on BAL samples	B	II	Retrospective study. Sensitivities for LFD, GM, BDG and PCR were between 70% and 88%. Combined GM (cut-off >1.0 OD) with LFD increased the sensitivity to 94%, while combined GM (cut-off >1.0 OD) with PCR resulted in 100% sensitivity (specificity for probable/proven IPA 95%–98%).	[430]

Abbreviations: BAL, bronchoalveolar lavage; BDG, β -D-glucan test; GM, galactomannan; HSCT, haematopoietic stem cell transplantation; IA, invasive aspergillosis; IFD, invasive fungal diseases; LFD, lateral device flow; NPV, negative predictive value; PCR, polymerase chain reaction; PPV, positive predictive value; QoE, Quality of evidence; SoR, Strength of recommendation.

Table 10
PCR on bronchoalveolar lavage or cerebrospinal fluid

Population	Intention	Intervention	SoR	QoE	Comment	Ref.
Patients undergoing allogeneic stem cell transplantation recipients not on mould-active prophylaxis	To diagnose IA	BAL PCR	B	II		[431]
Patients with pulmonary infiltrates and haematological malignancies and prolonged neutropenia	To diagnose IA	BAL PCR	B	II	Methodically different in-house assays, better performance in patients without antifungal treatment, PCR and galactomannan: increases specificity	[353,411,430,432–452]
ICU patients, mixed populations	To diagnose IA	BAL PCR	B	II	Commercially available <i>Aspergillus</i> PCR assays with good performance data	[81,88,450,453–455]
Patients with haematological malignancies	To diagnose CNS aspergillosis or meningitis	CSF PCR	B	II	113 CSF samples from 55 immunocompromised patients sensitivity 100%, specificity 93% (retrospective)	[415,456–459]

Abbreviations: BAL, bronchoalveolar lavage; CNS, central nervous system; CSF, cerebrospinal fluid; IA, invasive aspergillosis; ICU, intensive care unit; QoE, Quality of evidence; SoR, Strength of recommendation.

Table 11
PCR on whole blood, serum or plasma

Population	Intention	Intervention	SoR	QoE	Comment	Ref.
Patients with haematological malignancies	To diagnose IA	PCR on blood samples	B	II	Meta-analysis: 16 studies PCR single positive test: Sensitivity: 88%, specificity: 75%; PCR two consecutive positive tests: Sensitivity: 75%, specificity: 87%	[460]
	To diagnose IA	PCR on serum samples			97% of protocols detected threshold of 10 genomes/mL serum volume >0.5 mL, elution volume <100 μ L, sensitivity: 86%; specificity: 94%	[461]
	To diagnose IA	PCR on whole blood samples			First blood PCR assay to be compatible with EAPCRI recommendations, fever driven: Sensitivity: 92%, specificity: 95%, negative PCR result to be used to rule out IA	[462]
Haematopoietic stem cell transplantation	To diagnose IA	Prospective screening PCR on whole blood samples	B	II	Combination of serum and whole blood superior	[94–97]
	To diagnose IA	Prospective screening PCR on blood samples	B	II	Addition of GM and PCR monitoring provides greater accuracy, PPV 50%–80%, NPV 80%–90%	[98]
	To diagnose IA	PCR and GM in BAL	A	II		[393]

Abbreviations: BAL, bronchoalveolar lavage; EAPCRI, European *Aspergillus* PCR Initiative; GM, galactomannan; IA, invasive aspergillosis; NPV, negative predictive value; PCR, polymerase chain reaction; PPV, positive predictive value; QoE, Quality of evidence; SoR, Strength of recommendation.

Table 12
Molecular diagnostics on biopsies

Population	Intention	Intervention	SoR	QoE	Comment	Ref.
Biopsy with visible hyphae	To detect and specify a fungus	Broad-range PCR	A	II	High sensitivity (>90%) and high specificity (99%); various molecular-based techniques available	[61,463]
Biopsy with no visible hyphae	To detect and specify a fungus	Broad-range PCR	C	II	Sensitivity (57%) and specificity (96%); ability to distinguish other fungi; performance only in addition to other tests	[61,463]
Biopsy with visible hyphae	To detect and specify a fungus	Broad-range PCR on wax-embedded specimens	A	II	TaKaRa DEXPAT kit and QIAamp DNA mini kit detected fewer than 10 conidia/sample	[464,465]
Any	To detect and specify a fungus	Fresh tissue samples	B	II	<i>Aspergillus</i> PCR performance analysis yielded sensitivity/specificity rates of 86%/100% (79 patients, retrospective study)	[58]

Abbreviations: QoE, Quality of evidence; SoR, Strength of recommendation.

Table 13
Storage of original samples and isolates

Population	Intention	Intervention	SoR	QoE	Comment	Ref.
Any	To prevent loss of viability of <i>Aspergillus</i> in clinical samples, and to reflect the original fungal content	Clinical samples for culture—short-term storage: 4°C to prevent loss of viability and to reflect the original fungal content	A	III		[98,378]
	To prevent degradation of biomarkers, e.g. GM in serum or BALs or bronchial washes	Complete assay soon after delivery to laboratory. Avoid short-term or long-term storage of serum at 4°C	A	I	GM in serum degrades with short-term and long-term storage at 4°C; BAL fluid GM ODI remain stable; testing of pos./neg. serum and BAL fluid pools showed no decline in GM index over 11 months at –20°C	[61,80,369,370,392]
	Short-term maintenance of <i>Aspergillus</i> isolates	Repeated sub-culture	A	I	Viability maintained for several years by frequent sub-culture; transfer once a month; maintain at average ambient room temperature	[98,378]
	Long-term preservation of <i>Aspergillus</i> isolates	Water storage/storage under mineral oil/silica gel storage/freeze-drying freezing (–80°C/ceramic beads/liquid nitrogen)	A	I	Long-term storage means storage periods of 5 years or longer; no further transfers required during this period	

Abbreviations: BAL, bronchoalveolar lavage; GM, galactomannan; ODI, optical density index; QoE, Quality of evidence; SoR, Strength of recommendation.

Table 14
Antibody-based diagnosis of invasive aspergillosis [11]

Population	Intention	Intervention	SoR	QoE	Comment	Ref.
Any	To diagnose IA	<i>Aspergillus</i> -specific antibodies by EIA: Serion (Germany), Omega (France), Bio-Rad (France), Dynamiker (China)	C	II	Antibodies take a mean of 11 days to develop after onset of illness; detectable in 29% to 100% of patients during course of acute IA	[52,466–472]
		Precipitating antibodies by agar gel double diffusion (Microgen Ltd. UK) or counter-immunoelectrophoresis	C	III	Consider false-negative results due to hypogammaglobulinaemia	[473]
		Agglutinating antibodies by indirect haemagglutination (EliTech/Fumouze, France)	C	II		[473]
		Specific immunoglobulins to <i>Aspergillus</i> by ImmunoCap®	C	III		No reference found

Abbreviations: EIA, enzyme immunoassay; IA, invasive aspergillosis; QoE, Quality of evidence; SoR, Strength of recommendation.

Table 15
Indications for testing for azole resistance in clinical *Aspergillus* isolates

Population	Intention	Intervention	SoR	QoE	Comment	Ref.
All clinically relevant <i>Aspergillus</i> isolates (in patient groups or regions with known azole resistance)	Identify azole resistance	Reference MIC testing	A	II	In situations where rapid testing is available	[105,111,114,116,300,474–484]
Clinically relevant <i>Aspergillus</i> isolates in patient groups with high prevalence of azole resistance or patients unresponsive to treatment	Identify isolates with intrinsic resistance	Species identification to complex level	A	III	Some species are intrinsically resistant—e.g. <i>A. calidoustus</i> (azole resistant) and <i>A. terreus</i> (AmB resistant)	[103,485]
Clinically relevant <i>A. fumigatus</i> isolates	Identify azole-resistant <i>A. fumigatus</i>	Routine azole agar screening	B	III	Identifies resistant colonies that require MIC-testing	[118,486]
All isolates—resistance surveillance	Determine the local epidemiology of azole resistance	Periodical reference MIC testing of <i>A. fumigatus</i> complex	A	II	Test at least 100 isolates	[105,111,114,300,477–480,482–484]
Azole-resistant isolates	Determine nature and trends in Cyp51A mutation distribution	Cyp51A-gene mutation analysis	A	II	Test resistant isolates from surveillance survey	[107]

Abbreviations: AmB, Amphotericin B; MIC, minimum inhibitory concentration; QoE, Quality of evidence; SoR, Strength of recommendation.

Antifungal susceptibility testing of *Aspergillus* isolates should be performed in patients with invasive disease with the exception of azole-naïve patients in regions with no resistance found in contemporary surveillance programmes and regularly for epidemiological purposes including ≥ 100 isolates. This is particularly important in patients who are unresponsive to antifungal treatment, or in patients who are clinically suspected of having an azole-resistant pathogen (**AIII**) (Table 15). If MIC testing is not available, routine agar screening can be used to detect azole resistance

(Table 16) [118]. However, such isolates should be referred to a mycology reference laboratory for MIC testing. Clinical breakpoints for interpretation of azole and amphotericin B MICs against *Aspergillus* are currently available for the European Committee on Antimicrobial Susceptibility Testing (EUCAST) microdilution method but remain undetermined for Clinical & Laboratory Standards Institute (CLSI) methodology. Accordingly, EUCAST (**AII**) or CLSI broth microdilution methods (**BII**) can be used for determination of routine MICs for clinical guidance and for epidemiological

Table 16
Azole susceptibility testing: timing, methods, and number colonies

Population	Intention	Intervention	SoR	QoE	Comment	Ref.
Any	Confirm or reject azole resistance in clinical <i>A. fumigatus</i> isolates when antifungal treatment is considered Detect azole-resistant <i>A. fumigatus</i> genotypes in a single culture	Azole agar screening test followed by reference MIC test where needed	A	III	MIC testing as soon as the strain is isolated and without waiting for species ID	[103,114]
		Reference MIC testing of multiple colonies (up to five colonies)	B	III	Multiple genotypes, i.e. azole-susceptible and azole-resistant, may be present	[115,487,488]
		Routine azole agar screening (up to five colonies)	B	III	One resistant colony can be identified among four susceptible samples together as recently validated	[118,486]
	Confirm or reject azole resistance by a validated method	MIC test using EUCAST method and EUCAST BPs (S, I, R)	A	III	Applicable to all <i>Aspergillus</i> spp. Breakpoints established for most species	[489–491]
		MIC test using CLSI method and CLSI ECVs (wild-type/non-wild-type)	B	III	Breakpoints not established	[491]
MIC testing of various <i>Aspergillus</i> spp.	Etest®	C	III	Confirmation by reference test recommended	[492–496]	

Abbreviations: MIC, minimum inhibitory concentration; QoE, Quality of evidence; SoR, Strength of recommendation.

Table 17
Azole MIC testing: choice of azole compounds

Population	Intention	Intervention	SoR	QoE	Comment	Ref.
Any	To determine susceptibility to itraconazole	MIC (EUCAST/CLSI)	A	III	In general, a sensitive marker for azole resistance in <i>Aspergillus</i> ; test itraconazole and voriconazole as a minimum	[490,491,497–501]
Any	To determine susceptibility to voriconazole	MIC (EUCAST/CLSI)	A	III	Resistance/reduced susceptibility to other azole(s) may accompany that of voriconazole; isolated voriconazole resistance described related to TR ₄₆ mutation	[114,489,491,499–502]
Any	To determine susceptibility to posaconazole	MIC (EUCAST/CLSI)	B	III	Posaconazole resistance without itraconazole resistance not reported so far; current EUCAST breakpoint will misclassify approximately 15% susceptible isolates as I/R	[300,481,490,491,499–504]
Any	To determine susceptibility to isavuconazole	MIC (EUCAST/CLSI)	A	III	MIC often similar to voriconazole, but needs testing separately, if isavuconazole is to be used; lower MIC of isavuconazole as compared to itraconazole and voriconazole for <i>A. lentulus</i> and <i>A. udagawae</i> (<i>A. fumigatus</i> complex) (CLSI)	[490,499,500,502,505–507]

Abbreviations: CLSI, Clinical & Laboratory Standards Institute; EUCAST, European Committee on Antimicrobial Susceptibility Testing; MIC, minimum inhibitory concentration; QoE, Quality of evidence; SoR, Strength of recommendation.

resistance surveillance (**AII**). Both itraconazole and voriconazole (**AII**) should be tested to ensure detection of the voriconazole-resistance mutation TR₄₆/Y121F/T289A [118]. Posaconazole resistance without itraconazole resistance has not been reported (Table 17). EUCAST (**BIII**) or CLSI broth microdilution methods (**CIII**) can be used to determine amphotericin B MICs but although a correlation between MIC and clinical outcome exists for *Aspergillus terreus* and *Aspergillus flavus* it remains to be documented for *A. fumigatus* due to the scarcity of resistant isolates (Table 17).

Voriconazole and isavuconazole are recommended for the treatment of IA due to species showing high amphotericin B MICs (Table 18). Liposomal amphotericin B or amphotericin B lipid complex (ABLC) are recommended for species with intrinsic high azole MICs (Tables 19 and 20). In aspergillosis due to *A. fumigatus* specifically, voriconazole or isavuconazole are recommended if the isolate is voriconazole-susceptible (EUCAST MIC ≤ 1 mg/L) (**AI**). If resistant (voriconazole MIC >2 mg/L), liposomal amphotericin B therapy is recommended (**AIII_u**). It is unknown if patients infected with *A. fumigatus* with voriconazole MIC 2 mg/L (intermediate), respond less well to voriconazole monotherapy. These patients may have an increased probability of failing voriconazole monotherapy, and combination therapy with an echinocandin or liposomal amphotericin B monotherapy should be considered for invasive disease (**AIII**) (Table 20). In azole-resistant CPA, liposomal amphotericin B or micafungin can be considered (**BII**) if surgical intervention is precluded [11]. In settings with environmental azole resistance, no change to the primary regimen for IA is recommended when resistance rates are $<10\%$ (**AIII**). If azole resistance

rates are $>10\%$, first-line therapy with voriconazole plus echinocandin (**BIII**) or liposomal amphotericin B (**BIII**) is recommended.

Therapeutic drug monitoring

Patients with IA often have multiple conditions associated with their underlying disease and its treatment that affects the absorption, distribution, metabolism and clearance of antifungal medications [119]. As a result, standardized dosing recommendations for antifungals used in the prevention or treatment of IA may not achieve effective or safe drug exposures in all patients. Moreover, a subset of patients with severe infections or difficult to treat sites (e.g. CNS) or infections caused by *Aspergillus* spp. with elevated MICs may require higher drug exposures. Therapeutic drug monitoring (TDM) is often the most direct laboratory approach for identifying patients at jeopardy for treatment failure or toxicity because of inadequate or excessive drug exposures, and can be used to fine-tune antifungal dosing to improve the probability of optimal outcomes (Table 21).

Itraconazole

For itraconazole, a serum trough of 0.5–4 mg/L (measured by HPLC) is recommended for prophylaxis (**AII** (efficacy), **BII** (safety)) and a trough of 1–4 mg/L is recommended during the treatment of IA (**AII** (efficacy), **BII** (safety)) [120–125]. Itraconazole has an active metabolite, OH-itraconazole that is present in concentrations similar to those of the parent itraconazole compound (1:1) when

Table 18
Antifungal regimens in intrinsic resistance

Population	Intention	Intervention	SoR	QoE	Comment	Ref.
Amphotericin B MIC ≥ 1 mg/L	To cure IA	Replace AmB with azole, if azole tested susceptible	B	II		[17,170,515–520]
IA due to <i>A. terreus</i>	To cure IA	Voriconazole	A	II	Avoid AmB	[162,521,522]
		Isavuconazole	A	II		
		Posaconazole	B	III		
		Itraconazole	B	III		
IA due to <i>A. calidoustus</i>	To cure IA	Lipid formulation of AmB	A	II	Avoid azoles	[103,523]
IA due to <i>A. tubingensis</i> (<i>A. niger</i> complex)	To cure IA	Other than azole monotherapy	C	III	Higher azole MIC common, but no data on clinical impact	[496,524,525]
IA due to <i>A. lentulus</i> (<i>A. fumigatus</i> complex)	To cure IA	Other than azole monotherapy				
IA due to <i>A. alliaceus</i> (<i>A. flavus</i> complex)	To cure IA	Other than AmB monotherapy	C	III	Avoid AmB	[526]
IA due to <i>A. niger</i> complex	To cure IA	Other than itraconazole and isavuconazole	B	III	Isavuconazole, posaconazole, and voriconazole MIC in general one dilution higher compared with <i>A. fumigatus</i> ; itraconazole MIC in general two steps higher; limited clinical data	[496,507]
IA due to <i>A. nidulans</i>	To cure IA	Voriconazole	C	III	AmB MIC elevated, poor clinical responses in chronic granulomatous disease	[527,528]

Abbreviations: AmB, amphotericin B; IA, invasive aspergillosis; MIC, minimum inhibitory concentration; QoE, Quality of evidence; SoR, Strength of recommendation.

Table 19
Amphotericin B susceptibility testing

Population	Intention	Intervention	SoR	QoE	Comment	Ref.
Clinically relevant isolate	Confirm or reject AmB resistance when antifungal treatment is considered	MIC test	C	III	Acquired resistance to AmB is very rare and therefore correlation with clinical outcome has not been documented apart from the poorer outcome for high MIC species (<i>A. terreus</i> and <i>A. flavus</i> compared with <i>A. fumigatus</i>).	[508–511]
Clinically relevant isolate	Interpretation of MIC (EUCAST)	MIC test using EUCAST method and EUCAST break points (S, I, R)	B	III	MIC break points proposed for <i>A. fumigatus</i> and <i>A. niger</i> Epidemiological cut-offs established for <i>A. flavus</i> , <i>A. fumigatus</i> , <i>A. niger</i> and <i>A. terreus</i> <i>A. terreus</i> is not considered a good target for AmB. <i>A. flavus</i> may be <i>in vitro</i> resistant	[490,512,513]
Clinically relevant isolate	Interpretation of MIC (CLSI)	MIC test using CLSI method and CLSI ECVs (wild-type/non-wild-type)	B	III	ECVs proposed for <i>A. fumigatus</i> , <i>A. flavus</i> , <i>A. nidulans</i> , <i>A. niger</i> , <i>A. terreus</i> , <i>A. versicolor</i> . No clinical break points. <i>A. terreus</i> and <i>A. flavus</i> , e.g. with MIC below the ECV are not good targets for AmB. No clinical data that <i>A. fumigatus</i> with MIC 2 will respond to AmB although classified as wild-type according to CLSI ECVs.	[514]

Abbreviations: AmB, amphotericin B; CLSI, Clinical & Laboratory Standards Institute; ECV, epidemiological cut-off value; EUCAST, European Committee on Antimicrobial Susceptibility Testing; QoE, Quality of evidence; SoR, Strength of recommendation.

Table 20
Optimal therapy in documented azole-resistance

Population	Intention	Intervention	SoR	QoE	Comment	Ref.
Isolate with voriconazole MIC = 2 mg/mL	To cure IA	Voriconazole + echinocandin combination therapy or L-AmB monotherapy for IA (as well as for CPA)	A	III	The probability of voriconazole treatment failure may be higher than in voriconazole MIC <2	[529–532]
Isolate with voriconazole MIC >2 mg/mL	To cure IA	L-AmB	A	II _u	Posaconazole not licensed for primary treatment Patients with contra-indications to AmB and other azoles	[113,114,533] No reference found. [529] [534]
		AmB lipid complex	C	III		
		Voriconazole & anidulafungin	B	III		
		Posaconazole & caspofungin	C	III		
		Caspofungin or micafungin	C	III		No reference found.

Abbreviations: AmB, Amphotericin B; CPA, chronic pulmonary aspergillosis; IA, invasive aspergillosis; L-AmB, liposomal amphotericin B; QoE, Quality of evidence; SoR, Strength of recommendation.

patients are at pharmacokinetic steady state. OH-itraconazole concentrations may be reported separately when samples are analysed by HPLC or LC/MS/MS, but will be included in the overall report of 'itraconazole' concentrations if samples are analysed by bioassay [126,127]. Therefore, the target range for itraconazole is

higher when reported by bioassay (i.e. 3–17 mg/L) but may vary by laboratory depending on the reference standards used. Samples should be acquired within 5–7 days of starting therapy. Repeat TDM is recommended the following week to confirm that the patient remains in the therapeutic range, and repeated thereafter as

Table 21
Therapeutic drug monitoring

Clinical scenarios where antifungal therapeutic drug monitoring may be indicated	Examples, comments
Populations with increased pharmacokinetic variability	Impaired gastrointestinal function; hepatic dysfunction; children, elderly patients, obese patients, critically ill patients
Changing pharmacokinetics	Intravenous to oral switch, changing gastrointestinal function, changing hepatic or function, physiological-instability
Interacting medications	Patient receiving medication known to induce cytochrome P450 enzymes especially CYP3A4, antacids, proton-pump inhibitors (itraconazole capsules, posaconazole suspension), antiretroviral medications. Patients should have medication records screened using a drug interactions screening database before starting and stopping antifungals (example: www.fungalpharmacology.org , fungal-druginteractions.org , or http://www.aspergillus.org.uk/content/antifungal-drug-interactions)
Poor prognosis disease	Extensive or bulky infection, lesions contiguous with critical structures, central nervous system infection, multifocal or disseminated infection
Compliance concerns	Important issue with longer-term consolidation therapy or secondary prophylaxis in outpatient setting
Suspected breakthrough infection	Therapeutic drug monitoring can establish whether fungal disease progression occurred in the setting of adequate antifungal exposure
Suspected drug toxicity, especially neurotoxicity (voriconazole)	Exposure-response relationships are described for other toxicities (e.g. hepatotoxicity), the utility of therapeutic drug monitoring to prevent their occurrence is less well established

clinically indicated if there are changes in the patient's clinical condition, concomitant medications known to interact, or suspected toxicity (Table 22). Steady-state concentrations can often be predicted from earlier (non-steady) state samples through pharmacokinetic models or computerized dosage-assistance. In centres where these tools are available, sampling before day 5–7 may be preferable.

Voriconazole

A plasma trough concentration of 1–5.5 mg/L is considered adequate for most patients receiving voriconazole prophylaxis or treatment (AII, safety and efficacy) [128–133]. However, a trough of 2–6 mg/L (AII, safety and efficacy) is recommended in patients treated for severe infections (multifocal or disseminated disease, CNS infections, infection with pathogen with elevated MICs, e.g. an MIC of 2 mg/L) [130,131]. TDM is strongly recommended in children due to the much higher rates of drug elimination and potential for underdosing, especially with the lower voriconazole doses recommended in the past (AII) [134,135]. Plasma levels should be monitored between 2–5 days after initiation of therapy, and repeated the following week to confirm that the patient remains in the therapeutic range. Repeated monitoring is indicated until steady-state level in the therapeutic range is confirmed, if there are changes in the patient's clinical condition, concomitant medications, or suspected toxicity (Table 23).

Posaconazole

For patients receiving posaconazole suspension, a plasma trough of >0.7 mg/L is recommended during prophylaxis (BII, efficacy) [136,137]; and a trough of >1 mg/L is recommended if the patient is receiving treatment for suspected or documented IA (AII, efficacy) [138]. Currently, no studies have defined an upper plasma target that is associated with toxicity, although pharmacokinetic studies supporting the registration of the new posaconazole tablet and intravenous formulations with the EMA used a provisional cut-off of 3.75 mg/L [139–141]. Posaconazole plasma trough levels should be monitored on day 5 of therapy or soon thereafter, and repeated as clinically indicated.

For most patients prescribed posaconazole, we recommend using the newer tablet formulation (or intravenous formulation, if tablet formulation is contraindicated) rather than the suspension (AII), as tablets are more likely to consistently achieve target plasma levels and are less affected by gastrointestinally dependent drug interactions [139]. Currently, there is limited evidence to suggest that all patients receiving posaconazole tablets or intravenous formulation for prophylaxis require routine TDM; however, our opinion is that when treating suspected or documented *Aspergillus* infections, TDM could still be useful if the pathogen has elevated MICs, is unresponsive to treatment, or in the event of unexplained toxicity (BIII). Until further data are available, we recommend using TDM monitoring strategies and plasma trough

Table 22
Itraconazole therapeutic drug monitoring

Population	Intention	Intervention	SoR	QoE	Comment	Ref.
All patients receiving itraconazole treatment for IA	Improve efficacy	Measure serum trough level on day 5 of therapy or soon after	A	II	Target itraconazole level >1 mg/L to 4 mg/L by HPLC. Hydroxy-itraconazole metabolite concentrations generally reported separately by HPLC or LC/MS/MS methods, but included in 'itraconazole' concentration report by bioassay. Therapeutic range by bioassay may vary by laboratory but typically fall in the range of (3–17 mg/L)	[122,127,535–537]
All patients receiving itraconazole for prophylaxis for IA	Improve efficacy	Measure serum trough level on day 5 of therapy or soon after	A	II	Target itraconazole level >0.5 mg/L (HPLC) or >3 mg/L (bioassay)	[124]
Patients receiving itraconazole	Reduce toxicity	Measure serum trough level on day 5 of therapy or soon after	B	II	Toxicity was associated with itraconazole levels >17.1 mg/L by itraconazole bioassay, which correspond to ~4 mg/L by HPLC	[127]

Abbreviations: HPLC, high performance liquid chromatography; IA, invasive aspergillosis; LC, liquid chromatography; MS, mass spectrometry; QoE, Quality of evidence; SoR, Strength of recommendation.

Table 23
Voriconazole therapeutic drug monitoring

Population	Intention	Intervention	SoR	QoE	Comment	Ref.
All patients receiving voriconazole treatment for IA	Improve efficacy, safety and compliance	Measure plasma trough level after 2–5 days of therapy or soon after	A	II	Target range of 1–5.5 mg/L	[128–131,133,538–540]
		Repeat plasma trough level	B	II	Repeat during second week of therapy, additional samples as clinically indicated and outlined in the text	[128–131,133,538–540]
All patients receiving voriconazole prophylaxis for IA	Improve efficacy, safety and compliance of prophylaxis	Measure serum trough level after 2–5 days of therapy or soon after, and 4 days after change of dose	A	II	As above; most studies investigated voriconazole treatment rather than prophylaxis	[132,541,542]
Patients with IA due to <i>Aspergillus</i> strains of reduced azole susceptibility MIC 2 mg/mL	Improve efficacy of treatment for isolates with MIC 2 mg/mL	Measure serum trough level after 2 to 5 days of therapy or soon after and 4 days after change of dose	A	II	Trough >2 mg/L recommended on the basis of PK/PD analysis	[131,543]

Abbreviations: IA, invasive aspergillosis; MIC, minimum inhibitory concentration; PK/PD, pharmacokinetic/pharmacodynamic; QoE, Quality of evidence; SoR, Strength of recommendation.

targets as detailed above and suggested for the suspension formulation (Table 24).

Isavuconazole

Although dose–response and plasma concentration–response relationships for isavuconazole have been reported in animal models, limited data are currently available to define a target therapeutic range or support the need for routine TDM for this agent [142]. Our opinion is that TDM could still be useful in the clinical assessment or monitoring of patients receiving isavuconazole therapy (CIII) if patients are unresponsive to treatment, have unexpected toxicity, pharmacokinetic drug–drug interactions, or if isavuconazole is being used to treat pathogens with elevated MICs or sanctuary sites such as the CNS. In the absence of well-defined therapeutic targets, documentation of a plasma trough in the range of 2–3 mg/L (mean concentration range from phase II/III clinical studies) after day 5 (including loading doses) suggests adequate drug exposure (Table 25).

Flucytosine

In rare circumstances, flucytosine may be used in combination with other antifungals for the treatment of triazole-resistant

Aspergillus spp. In this scenario, weekly measurements of peak serum concentrations 2 h following an oral dose (AII) are needed to confirm that peak concentrations are 50–100 mg/L to reduce the risk of toxicity. Trough concentrations required for efficacy are unknown but a level of 25–50 mg/L is recommended based upon experience from cryptococcosis [143,144].

Hospital environment

Standards for the hospital environment in immunosuppressed adults and children require special attention. Patients need to be segregated from construction or renovation (AII_h), potted plants (BII), and flowers in wards and in patients' rooms (CIII) [145–150]. Published data support the recommendation to accommodate patients in special hospital rooms with positive air pressure and HEPA filters (BII) or laminar airflow (BII_h). However, data were with historical controls, underpowered, or described by multivariate analysis describing high-risk situations for IA [151–154]. Protective masks for patients are proven not to be effective outside the protected area (CII) [155]. Filters for water supply, especially in showers, are recommended (BII) [156–160]. No data are available to support regular environmental air sampling to prevent infections. However, indoor sampling is advisable to monitor filter efficacy (BIII) [161,162].

Table 24
Posaconazole therapeutic drug monitoring

Population	Intention	Intervention	SoR	QoE	Comments	Ref.
Patients receiving posaconazole suspension for treatment of IA	Improve efficacy, compliance	Serum trough level on day 5 of therapy or soon after	A	II	Target level >1 mg/L. Gastroresistant tablet or intravenous formulation preferred for most patients, consider switch to tablet or intravenous, if no therapeutic levels with oral suspension. Repeat determination as clinically appropriate. Prolonged half-life gives similar results for random sampling and true trough samples	[138]
Patients receiving posaconazole suspension for prophylaxis to prevent IA	Improve efficacy, compliance	Serum trough level on day 5 of therapy or soon after.	C	II	Target level >0.7 mg/L. Adequate tissue concentrations may occur despite serum concentration <0.7 mg/L. Repeat determination as clinically appropriate	[136,137,544–547]
Patients receiving posaconazole	Improve safety	Measure serum trough level on day 5 of therapy or soon after	C	III	If treatment failure or toxicity suspected, therapeutic drug monitoring may be indicated in patients receiving gastroresistant tablet or intravenous formulation. Posaconazole exposures between 0.5–3.75 mg/L are well studied and considered safe and effective with all three formulations. Posaconazole plasma levels above this exposure range may be associated with toxicity	[120,121]

Abbreviations: IA, invasive aspergillosis; QoE, Quality of evidence; SoR, Strength of recommendation.

Table 25
Isavuconazole therapeutic drug monitoring

Population	Intention	Intervention	SoR	QoE	Comment	Ref.
All patients receiving isavuconazole	Improve efficacy safety and compliance	Measure serum trough level on day 5 of therapy or soon after	C	III	Limited data to support routine TDM but may be indicated in the setting of treatment failure, drug interactions, or if toxicity is suspected The long half-life of isavuconazole (130 h) may support the use of TDM in some clinical situations to confirm drug clearance before starting medications metabolized by CYP3A4, especially chemotherapy agents	FDA advisory briefing documents

Abbreviations: FDA, US Food and Drug Administration; QoE, Quality of evidence; SoR, Strength of recommendation; TDM, therapeutic drug monitoring.

Treatment strategies

Two strategies are accepted for managing patients with haematological malignancy at risk for IA: (i) the patient receives primary prophylaxis or (ii) the patient receives no prophylaxis but is monitored at least twice weekly using biomarkers. The decision between the two strategies depends on local epidemiology, access to rapid diagnostics and patient characteristics. Breakthrough fungal diseases may appear through either symptoms or a disease-identifying biomarker or imaging result. Fig. 1 depicts a consensus algorithm for patient management.

Primary prophylaxis

At least three studies describe a number of patients who succumbed with IA missed before death [163–165]. Although diagnostic procedures have improved since then, they are not satisfactory. For this reason, patients known to be at high risk for IA may receive primary prophylaxis, especially patients with profound and prolonged neutropenia or with active graft-versus-host disease (GvHD) (Table 26).

Aspergillosis in haematological malignancy and haematopoietic stem cell transplantation

In patients treated for haematological diseases, prolonged severe neutropenia is the most important risk factor for the

development of IA. T-cell-depleted grafts, glucocorticosteroids and other immune suppressive drugs have been identified as further risk factors for IA in the later course after haematopoietic stem cell transplantation (HSCT), even in non-neutropenic patients [166]. In fact, up to two-thirds of patients with IA diagnosed after allogeneic HSCT are not neutropenic [167], and the median time of diagnosis of IA after allogeneic HSCT is 82 days (range, 3–6542 days) [168].

Treatment

Providing a definite diagnosis of IA is a continuously challenging endeavour for clinicians. The EORTC/MSG definitions are only designed for clinical studies. For clinical decision-making, these definitions could have a deleterious outcome as confirmation of a proven or probable diagnosis would delay the start of therapy [169]. Any patient at risk considered by the responsible clinician as having IA should receive antifungal therapy (AIII) (Tables 27 and 28). Physicians should consider switching from intravenous to oral therapy in stable and pharmacokinetically reliable patients. Treatment duration depends on clinical response and on immune reconstitution or recovery from GvHD. Good partial or complete remission requires no persistent clinical, including imaging (scarring allowed), or microbiological evidence of disease. The range of the duration of treatment (3 to >50 weeks) is huge and the evidence base to support any particular

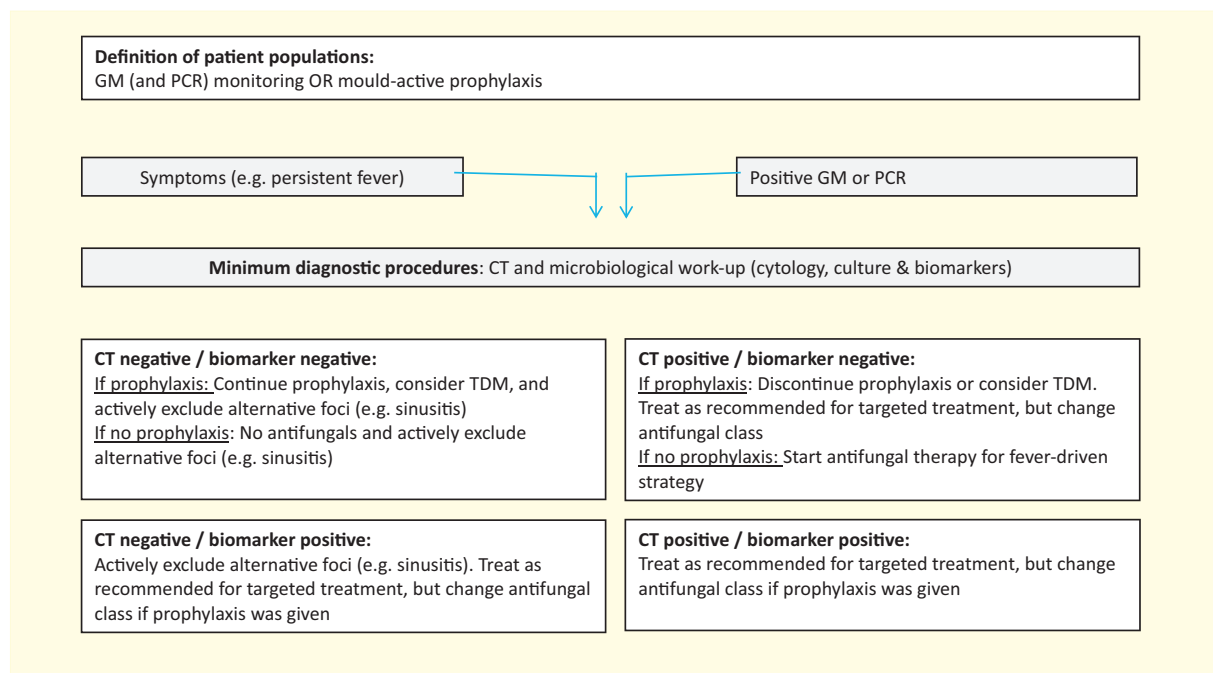


Fig. 1. Management during neutropenia.

Table 26
Primary prophylaxis

Population	Intention	Intervention	SoR	QoE	Comment	Ref.
Haematological malignancies, e.g. AML with prolonged and profound neutropenia	Lower incidence of IA	Posaconazole 200 mg tid suspension or 300 mg tablet qd	A	I	AML/MDS induction only. TDM especially with oral suspension. Tablets more bioavailable, bridging with posaconazole IV formulation possible	[548]
		L-AmB 12.5 mg 2 ×/weekly, nebulized, with undetermined dose of fluconazole	B	I	AML	[549,550]
		ABLC 3 mg/kg 3 ×/weekly	C	II _h	No difference to L-AmB regimen	[551]
		Micafungin 50 mg qd	C	II _t		[552,553]
		L-AmB 10 mg/kg q7d	C	II _u		[554]
		L-AmB 50 mg abs q2d	C	II _u		[555]
		L-AmB 15 mg/kg q14 d	C	II _u		[556]
		Voriconazole	C	II _t	Not better than fluconazole	[557]
		Itraconazole 400 mg/day, oral solution	D	II	No difference to fluconazole (n = 195) and more toxicity	[121,558–560]
		Acute lymphoblastic leukaemia, remission induction chemotherapy	Lower incidence of IA	L-AmB 5 mg/kg biw	D	I
Autologous HSCT or treatment of haematological malignancies besides acute leukaemia	Lower incidence of IA	Any mould active agent	D	III		No reference found.
Allogeneic HSCT (until neutrophil recovery)	Lower incidence of IA	Posaconazole 200 mg tid suspension or 300 mg tablet qd	B	II _t	Neutropenia duration approximately identical, TDM	[548]
		L-AmB 12.5 mg biw, nebulized, with fluconazole	B	II _t		[549]
		Voriconazole 200 mg bid	C	I	Not better than fluconazole, TDM	[557,562]
		Micafungin 50 mg/day	C	I	But no difference in subgroup analysis for aspergillosis	[552]
Allogeneic HSCT (after neutrophil recovery and no GvHD)		Itraconazole 400 mg/day oral solution	D	I	Toxicity issues; TDM	[549,560]
		Any antifungal agent	D	III	No study demonstrated outcome advantage	
Allogeneic HSCT (with moderate to severe GvHD and/or intensified immuno-suppression)		Posaconazole 200 mg tid suspension or 300 mg tablet qd	A	I	TDM	[563]
		Voriconazole 200 mg bid	C	II	Not better than fluconazole; TDM	[557,562]
		Itraconazole 400 mg/day, oral solution	C	II	Toxicity issues; TDM	[560]
		Micafungin 50 mg/day	C	III	Only few patients with GVHD	[552]
Allogeneic HSCT (until neutrophil recovery)	To reduce IA attributable mortality	Posaconazole 200 mg tid suspension or 300 mg tablet qd	B	II _t	Neutropenia duration approximately identical; TDM	[548]
		Any other antifungal	D	III	No study demonstrated outcome advantage	
Allogeneic HSCT (after neutrophil recovery, without GvHD)						
Allogeneic HSCT (with moderate to severe GvHD and/or intensified immuno-suppression)		Posaconazole 200 mg tid suspension or 300 mg tablet qd	A	II	Mainly IFD-attributable mortality, TDM	[563]

Abbreviations: ABLC, amphotericin B–lipid complex; AML, acute myeloid leukaemia; bid, twice daily; GvHD, graft-versus-host disease; HSCT, haematopoietic stem cell transplantation; IFD, invasive fungal disease; L-AmB, liposomal amphotericin B; MDS, myelodysplastic syndrome; qd, once daily; QoE, Quality of evidence; SoR, Strength of recommendation; TDM, therapeutic drug monitoring; tid, thrice daily.

recommendation is weak [170–173]. Close monitoring (e.g. non-enhanced CT or, if applicable, biomarkers) is suggested once antifungal treatment is discontinued.

Additional adjunctive therapy such as the administration of granulocyte colony-stimulating factor (G-CSF) or G-CSF-primed granulocyte infusions (data mainly from paediatric populations) received only a weak supportive recommendation (CIII). In refractory cases, G-CSF (or interferon- γ) has immunomodulatory effects [174–179]. No controlled trials have been performed and only anecdotal data with small numbers of patients exist. Persistent neutropenia is related with treatment failure, recovery from neutropenia enhances the efficacy of antifungal agents. A recent Cochrane review investigating the efficacy of granulocyte transfusions indicated no mortality difference for any kind of infection in patients with neutropenia [180].

Fever-driven ('empiric'), and diagnosis-driven ('pre-emptive') therapy

As an alternative to prophylaxis, patients could receive the classical empirical administration of antifungal agents during fever refractory to broad-spectrum antibacterial agents. Empiric

treatment is defined as a fever-driven treatment approach. Patients who would qualify for this approach are patients receiving induction or remission chemotherapy for acute leukaemia or myelodysplastic syndrome or conditioning chemotherapy for HSCT. Empiric antifungal treatment is expected to reduce morbidity [181–186] and mortality [187,188] (Table 29). The duration of empiric antifungal treatment is set by the following rules applied in randomized clinical trials. If the patient is afebrile and has no active infection or infiltrates, then antifungal therapy can be discontinued after recovery of leucocyte counts [188–190]. Today, antifungal stewardship may warrant clinical trials on empiric treatment duration, but no such trial has been conducted so far.

Pre-emptive treatment is a diagnosis-driven strategy. In most cases, it is defined by positive GM testing. However, chest CT with pulmonary infiltrates could apply as well. The use of BDG and PCR testing as alternative biomarkers for GM have considerable merit [191,192], though BDG is not specific for *Aspergillus* disease. In haematological patients, false-positive BDG often results from contaminated infusions [193–196]. Very few authors wait for *Aspergillus*-associated suggestive radiological signs including nodule, halo sign, wedge-shaped area of consolidation, or—late in the course of invasive aspergillosis—the air crescent sign, before

Table 27
Targeted therapy of pulmonary disease—first line

Population	Intention	Intervention	SoR	QoE ¹	QoE ²	QoE ³	Comment	Ref.
1] Neutropenia (non-allo HSCT recipients)	To increase response and survival rate	Isavuconazole 200 mg IV tid day 1–2, then 200 mg qd oral	A	I	II _t	II _t	D III, if mould active azole prophylaxis fewer adverse effects than voriconazole	[173,507,564,565]
2] Allo-HSCT (during neutropenia)		Voriconazole 2 × 6 mg/kg IV (oral 400 mg bid) on day 1, then 2–4 mg/kg IV (oral 200–300 mg bid)	A	I	II _t	II _t	C III for start with oral; D III, if prior mould active azole prophylaxis; TDM	[170,172,507,566]
3] Allo-HSCT (w/o neutropenia) or other non-neutropenic patients		L-AmB 3 mg/kg	B	II	II _t	II _t		[171]
		Combination of voriconazole 6/4 mg/kg bid (after 1 week oral possible (300 mg bid)) + anidulafungin 200/100 mg	C	I	II _t	II _t	No significant difference compared to voriconazole, in GM-positive (subgroup) better survival; TDM	[172,566]
		Caspofungin 70 mg qd day 1, followed by 50 mg qd (if body weight <80 kg)	C	II	II	II		[567–569]
		Itraconazole 200 mg q12 h IV on day 1, then 200 mg/qd	C	III	II _{t,a}	II _{t,a}	D III for start with oral, TDM D III, if mould active azole prophylaxis	[507,537]
		AmB lipid complex (ABLC) 5 mg/kg	C	III	III	III		[570]
		Micafungin 100 mg	C	III	III	III		[571–573]
		AmB colloidal dispersion (ABCD) 4–6 mg/kg	D	I	II _t	II _t		[142]
		Conventional AmB 1–1.5 mg/kg	D	I	II _t	II _t		[170]
		Other combinations	D	III	III	III	Efficacy unproven	[574]
Life-threatening haemoptysis	Bridging until neutrophil recovery	Arterial embolization, emergency surgical intervention	B	III	III	III		[575]

Abbreviations: allo-HSCT, allogeneic haematopoietic stem cell transplantation; AmB, amphotericin B; bid, twice daily; GM, galactomannan; IA, invasive aspergillosis; IV, intravenous; qd, once daily; QoE, Quality of evidence; SoR, Strength of recommendation; TDM, therapeutic drug monitoring; tid, thrice daily.

Table 28
Targeted therapy of extrapulmonary disease—first line

Population	Intention	Intervention	SoR	QoE	Comment	Ref.
Suspected or proven IA of the central nervous system	To increase response and survival rate	Surgical debridement, if surgically possible	A	II _u		[576,577]
		Voriconazole	A	II _u	<i>n</i> = 5/5 <i>n</i> = 81, 48 proven cases, 33 probable cases, TDM recommended targeting trough concentration of 2–5.5 mg/L	[170] [576]
		Posaconazole	D	III	8 patients documented in studies (5 failures)	[578]
		Itraconazole	D	III		
		Lipid formulations of AmB	B	III	Case collections, animal data	[579–581]
Patients with clinical suspicion of or proven invasive sinus aspergillosis	To cure	cAmB	D	I	Renal toxicity	[189,582–584]
		Echinocandins	D	III	Insufficient tissue penetration	[580]
		Surgery	A	III	Need to be considered on an individual basis and decision	
		Local antifungal therapy	C	III		
		Voriconazole	A	II _t	<i>n</i> = 8/7, TDM recommended	[170,585]
Patients with invasive sinus aspergillosis (all levels of certainty: suspected through proven)		L-AmB	A	II _t	Active against mucormycosis as well since mixed infections occur or cannot be differentiated	[171]
		Posaconazole, itraconazole, echinocandins	C	III	Not well specified in studies, TDM recommended for posaconazole and itraconazole	[586,587]

Abbreviations: AmB, Amphotericin B, cAmB, conventional amphotericin B; L-AmB, liposomal amphotericin B; QoE, Quality of evidence; SoR, Strength of recommendation; TDM, therapeutic drug monitoring.

starting antifungal treatment. Treatment choices are as recommended in targeted treatment.

Adult patients without haematological malignancy

Epidemiology

Approximately 43%–80% of the cases of IA appear in patients without a haematological malignancy [52,197–200], although these patients are rarely included in the seminal studies of antifungals [170,171,173]. The proportion of these patients is even increased when exposed to spore concentrations of >25 CFU/m³ in hospital air [201–204]. The non-haematological populations at risk

for IA include SOT recipients, patients treated with prolonged high-dose glucocorticosteroids, or with other immunosuppressants, patients with advanced AIDS or neoplasia, chronic obstructive pulmonary disease (COPD), liver failure, liver cirrhosis or influenza, as well as critically ill patients requiring admission to intensive care [52,197–199,205–208]. These patients frequently do not fulfil the EORTC/MSG criteria for invasive aspergillosis [169]. Confirmation of diagnosis may be delayed, resulting in high mortality rates. At the same time drug–drug interactions and toxicity can occur more frequently compared with haematological patients [52]. Physicians need to be aware of the specific risk factors, clinical manifestations and management challenges to improve outcome. In SOT recipients the average incidence of IA ranges from 0.1% to 11.6% [209,210],

Table 29
Fever-driven ('empiric') approach

Population	Intention	Intervention	SoR	QoE	Comment	Ref.
Chemotherapy for haematological malignancies or HSCT, neutropenia <500/ μ L \geq 96 h, fever (>38C), and parenteral broad spectrum antibacterial therapy \geq 96 h (some centres consider 48 h)	Reduction in the incidence of IA and/or related mortality	Caspofungin 70 mg qd day 1, followed by 50 mg qd (if body weight <80 kg)	A	I	Caspofungin was associated with a significantly higher rate of survival than L-AmB (subgroup analysis).	[188]
		L-AmB 3 mg/kg	B	I	Less toxicity in comparison to cAmB but more renal toxicity compared with echinocandin	[188,189]
		Voriconazole 6 mg/kg bid IV (oral 400 mg bid) on day 1, then 4 mg/kg bid IV (oral 200–300 mg bid)	B	II	Failed the 10% non-inferiority cut-off when compared with L-AmB, but first-line for aspergillosis. Activity of azoles empirical therapy for persistent fever may be limited in patients receiving prophylaxis with an agent of the same class. TDM	[190]
		Itraconazole 200 mg qd iv	C	II	Activity of azoles empirical therapy for persistent fever may be limited in patients receiving prophylaxis with an agent of the same class. TDM	[588]
		ABLC 5 mg/kg qd	C	I	Infusion-related toxicity (fever, chills, hypoxia)	[589]
		ABCD 4 mg/kg	C	I	Same as above	[590]
		cAmB 0.5–1 mg/kg qd	D	I	Poor tolerance due to extreme toxicity	[189,342,583,584,588,590]
		Micafungin 100 mg qd Fluconazole	B D	II II _r	No activity against <i>Aspergillus</i>	[591] [592]

Abbreviations: ABCD, amphotericin B colloidal dispersion; ABLC, amphotericin B lipid complex; cAmB, conventional amphotericin B; IV, intravenous; L-AmB, liposomal amphotericin B; QoE, Quality of evidence; SoR, Strength of recommendation; TDM, therapeutic drug monitoring.

with the highest risk in small bowel (11.6%) and lung (8.6%) transplant recipients, followed by patients receiving liver (4.7%), heart (4.0%), pancreas (3.4%) and kidney (1.3%) grafts [209–211]. Half the cases will occur in the first 3 months after transplantation, in patients with post-surgical risk factors. Late aspergillosis is more common in elderly recipients, and patients with pronounced immunosuppression due to rejection or post-transplant neoplasia or chronically impaired graft function [210,212]. With the exception of lung transplantation, in which universal prophylaxis is still common, antifungal prophylaxis will target SOT recipients with additional risk factors [211]. Risk factors for early IA in all SOT recipients—including heart transplants—comprise renal failure requiring replacement therapy, re-intervention, cytomegalovirus disease, and high environmental exposure to mould spores [211,213–215]. In liver transplantation, a high model for end-stage liver disease (MELD) score, transplantation in fulminant hepatic failure, high intraoperative transfusion needs or re-transplantation are considered indications for post-surgical prophylaxis [216–224]. In lung transplant recipients, risk factors include previous respiratory tract colonization with *Aspergillus*, single lung transplant, CMV disease and acquired hypogammaglobulinaemia [225–227]. In kidney transplantation risk factors include COPD, delayed graft function, bloodstream infection and acute graft rejection [228] and a >1.25 mg/kg/day average dose of prednisone [229]. Finally, some polymorphisms in defence genes have also been suggested to increase risk in transplant recipients [230,231].

The incidence of IA in HIV patients has decreased since the advent of new antiretroviral therapy (2.2 cases per 10 000/year), but mortality remains high (38%) [232]. IA typically appears in patients with low CD4 counts and associated conditions such as neutropenia, advanced cirrhosis, liver transplantation or glucocorticosteroid therapy [233–241]. As in other non-haematological populations, EORTC/MSG criteria only detect half of the IA cases diagnosed among HIV-infected patients [232] and in a recent series of autopsies of AIDS patients, only 12% of the patients with IA had been diagnosed ante mortem [242] (Table 30).

Invasive aspergillosis may affect 0.3% of patients with liver cirrhosis [243]. Both acute liver failure and advanced cirrhosis, mainly alcoholic hepatitis treated with glucocorticosteroids, have been recognized as risk factors for IA [205,244–246]. A low level of clinical suspicion explains that 53% of the cases of IA in cirrhotic patients are only recognized post-mortem [247] and that liver disease is independently associated with IA-related mortality [199,248].

Invasive aspergillosis has also been described in apparently immunocompetent patients in a critical condition as a complication of acute respiratory distress syndrome, COPD, influenza, pneumonia, burns, severe bacterial infection, surgery and malnutrition. Incidence is 4 to 6/1000 intensive care unit admissions and the mortality is higher than 70% in most series [245,249–252]. Glucocorticosteroid treatment was the major host factor [253,254] and as in cirrhotic or HIV-positive patients delayed diagnosis is common [255,256]. Individuals with COPD requiring glucocorticosteroids represent a group with especially high mortality [249,257,258]. Risk factors include admission to an intensive care unit, chronic heart failure and antibiotic treatment and, above all, the cumulative dose of glucocorticosteroids [257].

Pulmonary and CNS aspergillosis predominates in these populations, but disseminated disease, fulminant and atypical forms may occur [203,214,225,251,259–267]. The sensitivity of most diagnostic methods is lower in non-haematological patients. Isolation of *Aspergillus* from respiratory cultures has a much lower positive predictive value so over-diagnosis has to be prevented [197,268–272]. Regarding imaging findings, angioinvasive presentation included in the EORTC/MSG criteria is uncommon in this setting [273]. Airway invasive radiological presentation was present in 37% of heart transplant recipients and was associated with delayed diagnosis and poorer prognosis [214,274]. In COPD and HIV-positive patients, the most common radiological presentation was an alveolar infiltrate [273,275,276]. Experience with biomarkers and PCR is still scarce in these populations, but the combination of at least two different methods appears to be the best diagnostic approach [277–285] (Table 31).

Table 30
Non-haematological patients at high risk

Population	Intention	Intervention	SoR	QoE	Ref.
SOT lung with pre-transplantation colonization and <i>Aspergillus</i> in intraoperative culture OR CMV disease OR higher donor age OR prolonged ischaemia time OR receiving daclizumab OR bronchial anastomotic ischaemia OR bronchial stent OR single lung SOT	To identify patients with high risk of IA	Consider prophylaxis	B	III	[210,226,593] [215,594–596]
SOT lung with repeated acute and chronic rejection			B	II _t	[597,598]
SOT heart with re-operation, CMV infection, haemodialysis, other episode of IA in the program within 2 months	To identify patients with high risk of IA	Consider prophylaxis	A	II _h	[204]
SOT heart with airborne <i>Aspergillus</i> spores in ICU			A	II	[203,204]
SOT heart with sirolimus OR tacrolimus OR hypogammaglobulinaemia			B	II _h	[212,599]
SOT liver with one of the following characteristics: requirement for dialysis OR re-transplantation OR fulminant hepatic failure OR MELD score >30	To identify patients with high risk of IA	Consider prophylaxis	B	II _h	[210,211,217,224,308,311,600,601–604]
SOT liver with one of the following characteristics: ICU admission or corticosteroid requirement previous 2–4 weeks to transplant OR >15 units of packed red blood cells during transplant surgery OR reoperation involving the intra-abdominal cavity OR choledochojejunostomy			C	III	
SOT kidney with one of the following characteristics: pre-transplant COPD OR delayed graft function OR post-transplant bloodstream infection OR acute graft rejection	To identify patients with high risk of IA	Consider prophylaxis	A	II _h	[228]
COPD with one of the following characteristics: high (systemic) cumulative glucocorticosteroid dose OR refractory to antibiotic therapy OR admission to the intensive-care unit	To identify patients with high risk of IA	Consider prophylaxis	A	II _t	[232,257,605,606]
HIV with CD4 count <100 cells/ μ L	To identify patients with high risk of IA	Consider prophylaxis	A	II _h	[232]
ICU patients with either COPD OR requiring glucocorticosteroids therapy	To identify patients with high risk of IA	Consider prophylaxis	A	II _h	[257,605,606]
ICU patients with either acute liver failure OR burns OR severe bacterial infection OR malnutrition			B	III	
ICU or SOT recipients with increased environmental exposure	To identify patients with high risk of IA	Consider prophylaxis	A	II	[203,204,607,608]
Liver insufficiency	To identify patients with high risk of IA	Consider prophylaxis	B	II _h	[244,609]
Burn patients with positive fungal cultures	To identify patients with high risk of IA	Consider prophylaxis	A	II _h	[610,611]
Percentage of total body surface area burn injury; length of stay	To identify patients with high risk of IA	Consider prophylaxis	B	III	[608]
Patient receiving one of the following: tumour necrosis factor- α blockers, basiliximab, daclizumab, infliximab, etanercept, alemtuzumab, adalimumab, rituximab, abatacept	To identify populations at high risk of IA	Consider prophylaxis	C	III	No reference found

Abbreviations: BAL, bronchoalveolar lavage; CMV, cytomegalovirus; COPD, chronic obstructive pulmonary disease; IA, invasive aspergillosis; ICU, intensive care unit; QoE, Quality of evidence; SoR, Strength of recommendation; SOT, solid organ transplantation.

Treatment

Despite no comparative studies of antifungal therapy in non-haematological patients voriconazole remains the first option, as it has been related to reduced mortality [216,286–288] (Table 32). Combination therapy is uncommon, although retrospective data were encouraging in SOT recipients [289]. The risks of drug–drug interactions and toxicity are very important in these populations and TDM is advisable [290–295]. In patients with liver insufficiency, liposomal amphotericin B is usually the first therapeutic option. Antifungal resistance is not a common problem despite prophylaxis [296,297], although some cases have been reported [298–300]. Finally, immune reconstitution syndrome may occur after therapy initiation [301].

Most lung recipients receive antifungal prophylaxis. Targeted prophylaxis is preferred in the remaining SOT with risk factors [211,213,302–305]. However, significant variation in practice has been noted [221,304,306,307]. To avoid drug–drug interactions and toxicity, echinocandins or inhaled amphotericin are preferentially used [308–311], although voriconazole has also demonstrated its efficacy and safety in this setting [217,220,312–314]. Duration of prophylaxis is adjusted to the presence of risk factors and, with the exception of lung recipients, is usually limited to 3–4 weeks [215] (Table 33).

Special considerations in children

Presenting symptoms, distributions and patterns of diseases and vulnerability to IA are similar between children and adults. However, differences exist in epidemiology and underlying conditions, usefulness of newer diagnostic tools, pharmacology of antifungal agents and evidence from interventional phase III studies. Recommendations for paediatric patients are based on efficacy in phase II and III trials in adults, the availability of paediatric pharmacokinetic data, safety data and supportive efficacy data. In addition, regulatory approval is considered. Therapeutic drug monitoring is always recommended when mould-active azoles are used as prophylaxis or treatment.

Primary antifungal prophylaxis may be indicated in paediatric patients at ‘high risk’ for developing invasive fungal diseases, and specifically IA. An incidence rate of IFDs of $\geq 10\%$ is usually considered as high risk. High-risk populations include children with de novo or recurrent leukaemia (e.g. acute myeloid leukaemia, acute lymphoblastic leukaemia depending on treatment protocol), bone marrow failure syndromes with profound and persistent neutropenia (e.g. myelodysplastic syndrome, very severe aplastic anaemia), allogeneic HSCT recipients, patients with chronic granulomatous disease and those undergoing lung transplantation. For patients with haematological disorders, the mould-active oral

Table 31
Diagnosis-driven ('pre-emptive') approach in non-haematological patients

Population	Intention	Intervention	SoR	QoE	Comment	Ref.
COPD	To diagnose IA	Respiratory culture	A	II _u	Isolation of <i>Aspergillus</i> in culture from admitted patients with COPD represents IA in at least 22% of patients	[257,281,282,399]
COPD	To diagnose IA	GM BAL	B	II _u	Sensitivity/specificity of BAL GM >1.0 cut-off is 67%/96%, at GM >0.5 cut-off is 89%/88%	[281]
Underlying respiratory disease	To diagnose IA	Lateral flow device BAL	C	II	Sensitivity/specificity 77%/92% (Not commercially available at the time of writing)	[285]
HIV	To diagnose IA	Direct microscopy	A	II _h	50% positive	[232]
HIV	To diagnose IA	GM BAL	B	II _u	53% positive	[232]
HIV	To diagnose IA	GM serum	B	II _u	34% positive	[232]
HIV	To diagnose IA	Histology	A	II _u	75% positive	[232]
ICU	To diagnose IA	BDG serum	B	II _u	Autopsy study, non-haematological immunocompromised critically ill patients with lower respiratory tract infection. Using 140 pg/mL cut-off, sensitivity/specificity 100%/70%	[425]
ICU	To diagnose IA	BDG serum	B	II _u	BDG appeared a mean of 6.5 days before <i>Aspergillus</i> was grown	[427]
ICU	To diagnose IA	Respiratory culture	B	II _u		[89,612,613]
ICU	To diagnose IA	GM BAL	C	II _u	Using cut-off ODI 0.5 sensitivity/specificity 88%–90%/87%–100%	[89,612,613]
ICU	To diagnose IA	SeptiFast®	C	II _h	Sensitivity/specificity 66%/98%, PPV 93%, NPV 88%	[614,615]
ICU, others	To diagnose IA	BAL fluid samples	B	II _a	Sensitivity, specificity, and positive and negative predictive values of 80.0%, 93.3%, 80.0%, and 93.3%. This assay differentiates <i>A. fumigatus</i> and <i>A. terreus</i> , and detects azole resistance	[280]
Non-haematological	To diagnose IA	Culture	A	II _h	Very low PPV of <i>Aspergillus</i> spp. culture from respiratory samples	[197]
Non-haematological	To diagnose IA	Culture	A	II _h	Sensitivity of BAL higher for non-neutropenic patients	[52]
Non-haematological	To diagnose IA	GM serum	C	II	Using cut-off of 0.5 ng/mL sensitivity/specificity 60%/89%	[399]
Non-haematological	To diagnose IA	MycAssay Aspergillus®	C	II	Sensitivity, specificity, PPV, and NPV of first sample/any sample were 87%/93%, 87%/82%, 34%/34%, 92%/100%	[278]
SOT, any	To diagnose IA	Respiratory culture	D	II	Low sensitivity and specificity	[87,282]
SOT, any	To diagnose IA	GM BAL	B	II	Using cut-off ODI 1.0 sensitivity/specificity 100%/91%	[616]
SOT, any	To diagnose IA	High-resolution chest computed tomography	A	III	Bilateral bronchial wall thickening and centrilobular opacities, tree-in-bud pattern (65%), ground-glass opacities and/or bilateral areas of consolidation (23%)	[214,617]
SOT, any	To diagnose IA	Lateral flow device BAL	C	II	<i>n</i> = 11 SOT	[284,428,430]
SOT Heart	To diagnose IA	Respiratory culture	A	II _h	Overall positive predictive value (PPV) 60%–70%, PPV 88%–100% with respiratory specimens other than sputum; recovery of <i>A. fumigatus</i> PPV 78%–91%	[271]
SOT Heart	To diagnose IA	High-resolution computed tomography of the thorax	A	II _h	Provided significant additional information in 41%; positive with a normal chest X-ray in 18%	[274]
SOT Lung	To diagnose IA	BDG serum	C	II _u	Sensitivity/specificity 64%, 9%, PPV 14%, NPV 50%	[618]
SOT Lung	To diagnose IA	GM BAL	B	II	Using cut-off ODI 1.5 sensitivity/specificity 100%/90%	[87,88,400,619]
SOT Lung	To diagnose IA	PCR of respiratory samples	B	II		[88]

Abbreviations: BAL, bronchoalveolar lavage; BDG, β -D-glucan; COPD, chronic obstructive pulmonary disease; GM, galactomannan; HIV, human immunodeficiency virus; IA, invasive aspergillosis; ICU, intensive care unit; NPV, negative predictive value; ODI, optical density index; PCR, polymerase chain reaction; PPV, positive predictive value; QoE, Quality of evidence; SoR, Strength of recommendation; SOT, solid organ transplantation.

Table 32
Treatment in non-haematological patients

Population	Intention	Intervention	SoR	QoE	Comment	Ref.
HIV	To treat IA	Voriconazole	A	III	Consider drug–drug interactions with antiretroviral drugs.	[620]
SOT Heart	To treat IA	Itraconazole	C	III	6 patients cured with itraconazole 200–400 mg/day	[621]
SOT, any	To treat IA	Voriconazole	A	III	Erratic absorption and interaction with calcineurin inhibitors and other agents	[170,214,287,333,600,622–624,625–627]
SOT, any	To treat IA	Voriconazole	A	III	e.g. Herbrecht study 11 SOT; voriconazole increases the levels of anti-calcineurin immunosuppressors, TDM; monitor liver function tests especially in liver transplant recipients.	[628–630]
OT, any	To treat IA	L-AmB	A	II		[289]
SOT, any	To treat IA	Voriconazole & caspofungin	B	II	40 SOT voriconazole & caspofungin (<i>n</i> = 40) vs amphotericin B (<i>n</i> = 47). Survival benefit in patients with <i>A. fumigatus</i> or renal insufficiency	[631–634]
SOT, if voriconazole contraindicated	To treat IA	Caspofungin	B	III	Complete response 83%; response 7/9 monotherapy and 7/10 combination	[631–634]

Abbreviations: HIV, human immunodeficiency virus; IA, invasive aspergillosis; L-AmB, Liposomal amphotericin B; QoE, Quality of evidence; SoR, Strength of recommendation; SOT, solid organ transplantation; TDM, therapeutic drug monitoring.

Table 33
Prophylaxis in non-haematological patients

Population	Intervention	Intention	SoR	QoE	Comment	Reference
SOT Lung	Universal ^a prophylaxis	To prevent IA	A	I	Invasive fungal infection appeared at a median of 35 days	[304,315,635]
	Targeted ^a prophylaxis	To prevent IA	C	III		[315,595,636]
	Inhaled cAmB	To prevent IA	B	II _h	25 mg/day for 4 days, followed by 25 mg/week for 7 weeks. More adverse events in inhaled deoxycholate versus lipid-based	[637,638]
	Inhaled lipid-based AmB	To prevent IA	A	I	Breakthrough IA in 7%–10% More adverse events with inhaled deoxycholate versus lipid-based but similar efficacy; various possible protocols: 50 mg/day for 4 days, then 50 mg/week for 7 weeks; 50 mg/day for 2 weeks, then once weekly for 10 weeks; 25 mg thrice weekly between day 1 and day 60 post SOT and once weekly between day 60 and day 180	[625,637–640]
	Voriconazole	To prevent IA	A	III	Voriconazole 2×200 mg/day more hepatotoxic than itraconazole 2×200 mg/day. Usual duration of prophylaxis 3–6 months; monitor liver and skin toxicity	[303,304,315,636,641]
SOT Heart	Voriconazole pre-emptive, if colonized	To prevent IA	B	II _u	Breakthrough IA <2% at 6 months	[636]
	Voriconazole for 3 months	To prevent IA	C	II	No effect of voriconazole on the incidence of IA (45% versus 49%)	[303]
	Universal ^a prophylaxis with itraconazole or inhaled AmB	To prevent IA	C	I		[214,642,643]
	Universal ^a prophylaxis with itraconazole or inhaled AmB	To prevent IA	C	II	IA rates 5% without prophylaxis, 1.5% with itraconazole 2×200 mg, 0% with inhaled AmB	[214,642,643]
SOT Liver	Targeted ^a prophylaxis with echinocandins	To prevent IA	A	II _t	Prophylaxis in 10% of patients, IA rate reduced from 9% to 2%, attributable mortality from 6% to 2%; duration dependent of risk factors persistence	[215]
	Targeted ^a prophylaxis with lipid AmB	To prevent IA	B	III	IA rate reduced, mortality unaffected	[600,644–646]
	Targeted ^a prophylaxis with echinocandins	To prevent IA	A	I	Standard dosed echinocandins reduced IA rate; duration of prophylaxis usually 21 days post SOT	[217,308,311,647]

Abbreviations: AmB, Amphotericin B; cAmB, conventional amphotericin B deoxycholate IA, invasive aspergillosis; QoE, Quality of evidence; SoR, Strength of recommendation; SOT, solid organ transplantation.

^a Targeted prophylaxis = only if additional risk factors; universal prophylaxis = to all patients in population.

azoles are the first choice to prevent IA in children, although neither itraconazole nor posaconazole are licensed for use in patients <18 years of age. Due to the lack of paediatric data, recommendations for lung and high-risk liver transplant patients correspond to those given for adults [213,315]. Secondary prophylaxis to prevent recurrence of IA when risk factors are persisting is recommended with an antifungal targeted at the previous *Aspergillus* species, which caused the first episode (see below and Table 34).

Diagnostic procedures used in children are not different from those used in adults but their performance may differ. Suggestive abnormalities (e.g. halo sign, air crescent sign) on chest CT as described in adults are less common in children in which non-specific masses or infiltrates predominate [316–318]. The GM test on blood and BAL samples have a similar sensitivity and specificity profile compared with adults [319–327]. The BDG test is not specific for *Aspergillus* and is not validated in children. Higher baseline levels are reported in healthy children and therefore the cut-off is unknown [328–332].

General management principles of IA are consistent with those in adults and include prompt initiation of antifungal therapy, control of predisposing conditions (e.g. reduction or discontinuation of glucocorticosteroids in immunosuppressed, administration of colony-stimulating factors in neutropenic patients), and surgical interventions on a case-by-case basis using a multidisciplinary approach. Voriconazole is recommended as the first-line agent to treat IA in all children except neonates (AIII). Liposomal amphotericin B is first choice for neonates (AIII) and may replace voriconazole as first-line treatment in areas or institutions with a high prevalence of azole-resistant *A. fumigatus*. Upon diagnosis of invasive pulmonary aspergillosis, thorough evaluation for further sites of infection is required and should include the CNS. The optimal duration of therapy is determined by the resolution of all signs and symptoms and reversal of the underlying deficit in host defences. For salvage therapy and breakthrough

infections, a switch to a different class of antifungals is recommended [123,132,138,170,171,177,333–341] (Table 35).

If a fever-driven (empiric) strategy is used in at risk paediatric haematological patients, caspofungin or liposomal amphotericin B is recommended until resolution of fever and neutropenia [342–344]. Treatment recommendations for a diagnosis-driven (pre-emptive) strategy correspond to those made for targeted treatment [185,186,345,346].

Secondary prophylaxis

Secondary prophylaxis is a treatment strategy to prevent recurrence of IA during a subsequent risk period of immunosuppression. Patients with a history of IA previously successfully treated with antifungals entering a subsequent risk period of immunosuppression, e.g. allogeneic HCT (early phase), chemotherapy resulting in severe neutropenia (i.e. <500/μL and at least for 7 days), acute GvHD >I^o or extensive chronic GvHD, or T-cell-suppressing therapy, including steroids, are at risk. Agents for secondary prophylaxis are listed in Table 36.

Treatment of refractory disease

Refractory IA is defined as progression of disease and should be differentiated from stable disease [349]. Patients with radiological evidence of progression and persisting elevated GM have a very high probability of treatment failure resulting in death. Assessment of response should use composite outcome parameters including clinical, radiological and mycological criteria. Radiological progression following or closely preceding neutrophil recovery should be carefully evaluated and is not necessarily indicative of failure. Keeping this in mind, assessing the response 2 weeks after treatment initiation generally allows prediction of the response, especially recognizing oncoming failure [350]. In case of GM-negative

Table 34
Prophylaxis in children at high risk

Population	Intention	Intervention	SoR	QoE	Comment	Ref.
Allogeneic HSCT, pre-engraftment phase; Allogeneic HSCT, post-engraftment phase, GvHD and augmented immunosuppression; High-risk patients with <i>de novo</i> or recurrent leukaemia, bone marrow failure syndromes with prolonged and profound neutropenia	Prevention of IA	Itraconazole	A/B ^a	II _t	TDM recommended; Approved indication; not approved EU <18 years	[122,560,648–657]
		Posaconazole	A	II _t	TDM recommended; only supportive paediatric data for ≥13 years of age	[136,137,338,548,563,658–664]
		Voriconazole	A	II _t	Not approved for <2 years; Inference from efficacy from HSCT trials and supportive studies; TDM recommended	[130,131,135,541,557,562,665–671]
		Liposomal amphotericin B	B	II _t /III ^b	Not approved for prophylaxis; Optimal dose of alternate administration unknown; alternative if triazoles are not tolerated/contraindicated	[555,672–677]
		Micafungin	B	II _t /III ^b	No definite evidence (trend only) for prophylactic efficacy against <i>Aspergillus</i> spp. Alternative if triazoles are not tolerated or contraindicated	[552,678–682]
Chronic granulomatous disease patients	Prevention of IA	Itraconazole	A	II	Approved indication; not approved in the EU for <18 years; TDM recommended	[122,653–656,683,684]
		Posaconazole	A	III	Not EU approved for children <18 years; TDM recommended; PK and safety data for children ≥4 years	[136,137,660–663]

Abbreviations: GvHD, graft-versus-host disease; HSCT, haematopoietic stem cell transplantation; IA, invasive aspergillosis; PK, pharmacokinetics; QoE, Quality of evidence; SoR, Strength of recommendation; TDM, therapeutic drug monitoring.

^a SoR = B for allogeneic HSCT post-engraftment phase, GvHD and augmented immunosuppression.

^b QoE = III for allogeneic HSCT post-engraftment phase, GvHD and augmented immunosuppression.

Table 35
Treatment in children

Population	Intention	Intervention	SoR	QoE	Comment	Ref.
Any paediatric population other than neonates	Treatment proven/probable IA	Voriconazole 18 mg/kg/day IV day 1, followed by 16 mg/kg/day IV or 18 mg/kg/day PO in two divided dosages (up to 14 years and <50 kg); if > 15 years or >12 years and >50 kg use adult dosing recommendations	A	II _t	Not approved in patients <2 years; TDM recommended.	[130,131,135,170,333,541,667–670,600,622,623,685–688]
Any paediatric population other than neonates	Treatment proven/probable IA	L-AmB 3 mg/kg/day	B	II _t	Comparison between two dosages of L-AmB, no comparison to voriconazole	[171,675,677,689–692]
Any paediatric population other than neonates	Treatment proven/probable IA	Caspofungin 70 mg/m ² day 1, followed by 50 mg/m ² /day (max. 70 mg/day)	C	II _t	Study prematurely stopped due to low accrual	[691,567–569,631,632,693–698]
Neonates	Treatment proven/probable IA	L-AmB 3 mg/kg/day	A	III		[699–702]

Abbreviations: IA, invasive aspergillosis; IV, intravenous; L-AmB, liposomal amphotericin B; PO, *per os*; QoE, Quality of evidence; SoR, Strength of recommendation; TDM, therapeutic drug monitoring.

IA, early assessment of response may be difficult and could require a longer period of therapy. If failure is ascertained, look for poor vascular supply (i.e. sinusitis requiring surgical treatment), microbiological confirmation is recommended as identification of the fungus at the species level is pivotal. If a viable organism is recovered, susceptibility testing is recommended, especially regarding azole resistance. On the other hand, azole concentration should be monitored as well (see sections on resistance and therapeutic drug monitoring within this guideline) [38,85,349,351–357]. The choices of antifungal agents in refractory disease are listed in Table 37.

Chronic pulmonary aspergillosis

Chronic pulmonary aspergillosis is an indolent destructive disease of the lungs usually complicating other pulmonary conditions occurring in non- or mildly immunocompromised patients [358,359]. Its manifestations include chronic cavitary pulmonary aspergillosis (CCPA), which if left untreated may progress to chronic fibrosing pulmonary aspergillosis, *Aspergillus* nodule and single aspergilloma [11,360]. Subacute invasive pulmonary aspergillosis (previously chronic necrotizing pulmonary aspergillosis) is also a

cavitating destructive lung disease, usually found in moderately immunocompromised patients, which progresses more rapidly, typically over 1 to 3 months. The diagnosis of CPA requires a combination of characteristics: one or more cavities with or without a fungal ball present or nodules on thoracic imaging, either direct evidence of *Aspergillus* infection (culture or microscopy from biopsy) or an IgG antibody response to *Aspergillus* spp. and exclusion of alternative diagnoses (especially mycobacterial infection), all present for at least 3 months [11,361]. Over 90% of patients have circulating *Aspergillus* antibody (precipitins) (AII) [362]. A positive culture of *A. fumigatus* respiratory tract secretion (BAL, bronchoscopy aspiration) is not diagnostic because many different pathologies are attributable to the fungus, and it may be an airway-colonizing fungus or a plate contaminant in the laboratory.

If a fungal ball is seen, then only a positive test of *Aspergillus* IgG or precipitins confirms pathogenicity. Patients may have CPA and other infections concurrently (see below).

The distinctive hallmark of CCPA is new and/or expanding cavities with thick or thin walls in those with chronic lung disease. An intracavitary fungal ball may be present, often with pleural thickening and extensive parenchymal destruction and/or fibrosis. Patients may have CPA and other infections concurrently,

Table 36
Secondary prophylaxis

Population	Intention	Intervention	SoR	QoE	Comment	Ref.
Previous IA and undergoing allogeneic HSCT or entering risk period with non-resectable foci of <i>Aspergillus</i> disease	To reduce risk of IA recurrence	Secondary prophylaxis with an <i>Aspergillus</i> active antifungal proven to be effective in the actual patient	A	II	Results compared to historical data, mostly in allogeneic HSCT setting	[703–708]
		Voriconazole	A	II _h	IA: 31/45 patients, 1 year cumulative incidence of IFD 6.7 ± 3.6%, TDM	[703]
		Caspofungin 70 mg day 1, followed by 50 mg/day IV until stable engraftment, followed by 400 mg itraconazole suspension PO L-AmB followed by voriconazole	B	II _h		[707]
Previous IA and with resectable foci of <i>Aspergillus</i> disease before entering risk period	To reduce risk of IA recurrence	Surgical resection following by secondary prophylaxis	B	III	Fungal infection related mortality 28% despite lipid-based AmB Timing and methods of surgery important. Concomitant administration of appropriate antifungal compound justified Indication for surgical intervention by appropriate specialist. Interdisciplinary consensus needed	[706,709] [710–714]

Abbreviations: HSCT, haematopoietic stem cell transplantation; IA, invasive aspergillosis, IFD, invasive fungal disease; L-AmB, liposomal amphotericin B; PO, per os; QoE, Quality of evidence; SoR, Strength of recommendation; TDM, therapeutic drug monitoring.

Table 37
Antifungal drugs in refractory disease

Population	Intention	Intervention	SoR	QoE	Comment	Ref.
Haematological patients with refractory IA	Achieve complete or partial response, or stable disease, improve survival	Switch to another drug class	A	III		
		Any combination	C	III	No prospective study demonstrated superiority of combination therapy over monotherapy	[715]
		Voriconazole	A	II		[333,716,624,717]
		L-AmB 3–5 mg/kg	B	II	Majority voted for BII others for AII	[676,718,719]
		ABLC 5 mg/kg	C	II		[570,719,720,628]
		ABCD			No longer commercially available	[721,722]
		Caspofungin 70 mg qd day 1, followed by 50 mg qd (if body weight <80 kg)	B	II	Very few data in case of voriconazole/posaconazole failure	[335,717,723–727,633,728]
		Micafungin 75–200 mg qd	C	II		[572,729]
		Posaconazole 200 mg qid or 400 mg bid suspension or 300 mg tablet bid day 1, followed by 300 mg qd	B	II		[138,336,730,731]
		Itraconazole	D	III	In case of refractoriness to voriconazole	
Itraconazole oral forms	C	II	Poor bioavailability	[126]		
Itraconazole IV formulation			Commercially not available everywhere	[537,732]		

Abbreviations: ABCD, amphotericin B colloidal dispersion; ABLC, amphotericin B lipid complex; bid, twice daily; IV, intravenous; L-AmB, Liposomal amphotericin B; qd, once daily; qid, four times daily; QoE, Quality of evidence; SoR, Strength of recommendation; TDM, therapeutic drug monitoring.

Table 38
Chronic pulmonary aspergillosis

Population	Intention	Intervention	SoR	QoE	Comment	Ref.
Cavitary or nodular pulmonary infiltrate in non-immunocompromised patients	Diagnosis or exclusion of CPA	Direct microscopy for hyphae	A	II _t	Positive microscopy is a strong indicator of infection, not studied in CPA, but in ABPA	[733]
		Histology	A	II	In CPA histology distinguishes between CNPA and CCPA	[734]
		Fungal culture (respiratory secretion)	A	III	Bacterial culture plates are less sensitive than fungal culture plates	[269]
Cavitary or nodular pulmonary infiltrate in non-immunocompromised patients	Diagnosis or exclusion of CPA	<i>Aspergillus</i> IgG antibodies	A	II	IgG and precipitins test standardization incomplete	[362]
CPA patients with progressive disease	Control of infection	Itraconazole: Start 200 mg bid, adjust with TDM	A	II	No data to indicate which agent is preferable	[362,735]
		Voriconazole Start 150–200 mg bid, adjust with TDM			Voriconazole preferred for CNPA and patients with fungal balls to minimize risk of resistance	[364,736,737]
		Posaconazole 400 mg bid (oral suspension) 300 mg qd (delayed release tablets)	B	II	Higher rate of adverse events, if some adverse events with itraconazole and voriconazole	[738]

Abbreviations: ABPA, allergic bronchopulmonary aspergillosis; bid, twice daily; CCPA, chronic cavitary pulmonary aspergillosis; CNPA, chronic necrotizing pulmonary aspergillosis; CPA, chronic pulmonary aspergillosis; qd, once daily; QoE, Quality of evidence; SAIA, subacute invasive aspergillosis; SoR, Strength of recommendation; TDM, therapeutic drug monitoring.

especially bacterial including *Pseudomonas aeruginosa* infection or tuberculosis and non-tuberculous mycobacterial infection. *Aspergillus* nodules, which may be single or multiple, may mimic malignancy as well as nodules seen in rheumatoid arthritis, coccidioidomycosis, tuberculosis, non-tuberculous mycobacterial infection and, rarely, actinomycosis or rheumatoid arthritis. Typically, *Aspergillus* nodules appear rounded, some with low attenuation or cavitation within. Some are spiculated, a common feature of carcinoma [360].

If technically feasible, single aspergilloma should be surgically removed, preferably through a video-assisted thoracic surgery technique with due consideration for risks as recommended [363]. Long-term oral antifungal therapy is strongly recommended in patients with CCPA, partly to reduce general and respiratory symptoms [364,365], but also to minimize haemoptysis and prevent lung destruction and fibrosis (AII); itraconazole or voriconazole are effective for CCPA (AIII) [11]. Oral posaconazole is a potential alternative treatment (BII) [11]. Six months of therapy is the recommended minimum (AI) [11]. Relapse is common after discontinuation. Intravenous therapy for CPA is useful in patients who fail or are intolerant of triazoles or have triazole-resistant *A. fumigatus*. Prednisolone may be considered for underlying symptom control only if patients are adequately treated with antifungals. Mild and moderate haemoptysis usually responds to tranexamic acid; severe haemoptysis should be arrested with bronchial artery embolization (Table 38).

Conclusions

This executive summary is a comprehensive guideline covering many aspects of *Aspergillus* diseases. It provides guidance for clinicians on prevention of disease, diagnostic procedures, resistance issues and treatment of IA as well as CPA. The guideline group intends to provide additional publications supporting the rationale of the recommendations given.

Finally, the guideline group provides comprehensive tables explaining various options for specific situations.

Acknowledgements

Professor William Hope was a member of the TDM group; however, he stepped down during the process of guideline development due to his new post as guideline director of ESCMID to avoid any conflicts of interest. His contributions were very much appreciated to the entry guideline group. We are thankful for his help. We also thank Dr Vincent Dunet (Department of Diagnostic and Interventional Radiology, CHUV, Lausanne, Switzerland) and Dr Frédéric Lamoth (Department of Infectious Disease, CHUV, Lausanne, Switzerland) for their help and contribution to this guideline. We are indebted to Kerstin Albus, MSc, for her critical review and corrections of the manuscript.

Funding

European Society of Clinical Microbiology and Infectious Diseases (ESCMID), European Confederation of Medical Mycology (ECMM) and European Respiratory Society (ERS).

Transparency declaration

Dr Cornely reports research grants from Actelion, Amplyx, Arsanis, Astellas, AstraZeneca, Basilea, Bayer, Cidara, Duke University (NIH UM1A1104681), F2G, Gilead, GSK, Leeds University, Matinas, Medicines Company, MedPace, Melinta, Merck/MSD, Miltenyi,

Pfizer, Rempex, Roche, Sanofi Pasteur, Scynexis, Seres, is a consultant to Amplyx, Actelion, Astellas, Basilea, Cidara, Da Volterra, F2G, Gilead, Janssen, Matinas, Menarini, Merck/MSD, Paratek, PSI, Scynexis, Seres, Summit, Tetrphase, Vical, and received lecture honoraria from Astellas, Basilea, Gilead, Merck/MSD and Pfizer, outside the submitted work. Dr Ader has nothing to disclose. Dr Aguado received honoraria for speaking at symposia organised on behalf of Pfizer, Merck Sharp & Dohme (MSD), Schering-Plough and Gilead and was on advisory boards for antifungal agents on behalf of MSD, Astellas, Pfizer and Gilead. Dr Akova has nothing to disclose. Dr Arendrup reports personal fees from MSD and Pfizer, grants from Basilea, Gilead, Amplyx, F2G and Cidara, outside the submitted work. Dr Arikan-Akdagli reports non-financial support from Pfizer, outside the submitted work. Dr Barnes reports personal fees from Gilead, Basilea and Biomérieux, grants from EORTC, outside the submitted work. Dr Beigelman-Aubry reports personal fees from Gilead, outside the submitted work. Dr Blot reports grants from Pfizer, outside the submitted work. Dr Bouza has nothing to disclose. Dr Brüggemann has received grants and consultancy fees as well as speaker fees from MSD, Pfizer, Gilead and Astellas. All contracts were with Radboudumc and all payments have been received by Radboudumc. Dr Buchheidt reports personal fees and non-financial support from Astellas, personal fees from Basilea, grants, personal fees and non-financial support from Gilead, personal fees and non-financial support from Merck Sharp & Dohme/Merck, grants, personal fees and non-financial support from Pfizer, outside the submitted work. Dr Cadranet reports personal fees from MSD, outside the submitted work. Dr Castagnola reports personal fees from Astellas Pharma, non-financial support from Gilead, outside the submitted work. Dr Chakrabarti has nothing to disclose. Dr Cuenca-Estrella reports grants and other from Gilead and MSD, grants from Amplyx, Cidara, Scynexis and F2G, other from Astellas, outside the submitted work. Dr Denning and family hold Founder shares in F2G Ltd, a University of Manchester spin-out antifungal discovery company. He acts or has recently acted as a consultant to Astellas, Sigma Tau, Basilea, Scynexis, Cidara, Biosergen, Quintiles, Pulmatrix, Pulmocide and Zambon. In the last 3 years, he has been paid for talks on behalf of Astellas, Dynamiker, Gilead, Merck and Pfizer. He is a longstanding member of the Infectious Disease Society of America Aspergillosis Guidelines group, the European Society for Clinical Microbiology and Infectious Diseases Aspergillosis Guidelines group and the British Society for Medical Mycology Standards of Care committee. In addition, Dr Denning has a patent Assays for Fungal Infection licensed. Dr Dimopoulos has nothing to disclose. Dr Fortún has nothing to disclose. Dr Gangneux reports grants and personal fees from Pfizer, MSD, Gilead and Astellas during the conduct of the study. Dr Garbino has nothing to disclose. Dr Groll reports grants and personal fees from Gilead, Merck, Sharp & Dohme and Pfizer, personal fees from Astellas and Basilea, outside the submitted work. Dr Heinz reports personal fees from Astellas, Gilead and Basilea, grants and personal fees from MSD Sharp & Dohme/Merck and Pfizer, outside the submitted work. Dr Herbrecht reports personal fees from Astellas, Basilea, Gilead, MSD and Pfizer, outside the submitted work. Dr Heussel reports personal fees from Boehringer Ingelheim, Novartis, Gilead, Intermune and Fresenius, grants from Siemens, Pfizer and Boehringer Ingelheim, lecture fees from Gilead, MSD, Pfizer, Intermune, Novartis, Basilea and Bayer, outside the submitted work. Dr Heussel has a patent for Method and Device For Representing the Microstructure of the Lungs licensed. Dr Kibbler reports personal fees from Gilead, outside the submitted work. Dr Klimko reports personal fees from Astellas and Pfizer, and grants and personal fees from Merck, outside the submitted work. Dr Kullberg reports personal fees from Astellas, Amplyx, Cidara, Gilead, Pfizer and Scynexis, outside the submitted work. Dr Lagrou reports grants, personal fees and non-financial support from MSD, Pfizer

and Gilead, personal fees from Abbott, outside the submitted work. Dr Lange reports personal fees from Chiesi, Gilead, Abbvie, MSD, Becton Dickinson, Janssen, Lucane, Novartis, Thermofisher and Transgene, outside the submitted work. Dr Lass-Flörl reports grants, personal fees and other from Astellas Pharma and Gilead, personal fees and other from Pfizer, other from Merck Sharp and Dohme and Basilea, outside the submitted work. Dr Lehrnbecher reports grants, personal fees and non-financial support from Gilead Sciences, personal fees and non-financial support from Astellas and Merck/MSD, personal fees from Basilea, outside the submitted work. Dr Lewis reports personal fees from Gilead, grants and personal fees from Merck, personal fees from Cidara, outside the submitted work. Dr Loeffler has nothing to disclose. Dr Lortholary has nothing to disclose. Dr Maertens reports grants, personal fees and non-financial support from MSD, Astellas, Pfizer and Gilead, personal fees and non-financial support from Basilea and F2G, personal fees from Scynexis, during the conduct of the study. Dr Marchetti has nothing to disclose. Dr Meis reports personal fees and grants for consultancy from Astellas, MSD and Scynexis, grants from F2G and Pulmozyme, personal fees and grants for lectures including service on speakers' bureaus from Merck, Gilead and TEVA, grants for travel and accommodation from Nordic-Pharma, outside the submitted work. Dr Muñoz has nothing to disclose. Dr Pagano reports grants and personal fees from Gilead, personal fees from MSD, Pfizer, Novartis, Janssen and Basilea, outside the submitted work. Dr Ribaud has nothing to disclose. Dr Richardson reports other from Associates of Cape Cod, personal fees from Gilead and MSD, other from Gilead, during the conduct of the study. Dr Roilides reports grants, personal fees and non-financial support from Astellas, Gilead Merck and Pfizer, outside the submitted work. Dr Ruhnke reports personal fees from Basilea and Scynexis for board membership, personal fees from Basilea and Janssen for lectures including service on speakers bureaus, personal fees from Janssen for development of educational presentation, outside the submitted work. Dr Sanguinetti has nothing to disclose. Dr Sheppard reports grants and personal fees from Merck, outside the submitted work. Dr Sinko reports personal fees (honoraria, fees for consulting, lectures, speakers bureaus) from Pfizer, Merck, Astellas. Dr Skiada has nothing to disclose. Dr Ullmann reports personal fees from Pfizer, Astellas, MSD and Gilead, outside the submitted work. Dr Vehreschild reports personal fees, non-financial support and other from Astellas, during the conduct of the study; grants and personal fees from Astellas and Merck/MSD, grants from Seres Therapeutics and DaVolterra, grants and personal fees from Gilead, personal fees from Berlin Chemie, Falk Foundation, Organobalance and Pfizer, outside the submitted work. Dr Verweij reports grants from Gilead Sciences, MSD and F2G, outside the submitted work. Dr Viscoli reports personal fees from MSD, Gilead, Pfizer, Angelini, Astellas and Basilea, outside the submitted work. Dr Warris reports grants from Gilead, other from Gilead and Basilea, outside the submitted work.

Appendix A. Supplementary data

Supplementary data related to this article can be found at <https://doi.org/10.1016/j.cmi.2018.01.002>.

References

- Arendrup MC, Boekhout T, Akova M, Meis JF, Cornely OA. ESCMID and ECMM joint clinical guidelines for the diagnosis and management of rare invasive yeast infections. *Clin Microbiol Infect* 2014;20(Suppl. 3):76–98.
- Chowdhary A, Meis JF, Guarro J, de Hoog GS, Kathuria S, Arendrup MC, et al. ESCMID and ECMM joint clinical guidelines for the diagnosis and management of systemic phaeoconidiosis: diseases caused by black fungi. *Clin Microbiol Infect* 2014;20(Suppl. 3):47–75.
- Cornely OA, Arikan-Akdagli S, Danaoui E, Groll AH, Lagrou K, Chakrabarti A, et al. ESCMID and ECMM joint clinical guidelines for the diagnosis and management of mucormycosis 2013. *Clin Microbiol Infect* 2014;20(Suppl. 3):5–26.
- Cornely OA, Bassetti M, Calandra T, Garbino J, Kullberg BJ, Lortholary O, et al. ESCMID* guideline for the diagnosis and management of Candida diseases 2012: non-neutropenic adult patients. *Clin Microbiol Infect* 2012;18(Suppl. 7):19–37.
- Cuenca-Estrella M, Verweij PE, Arendrup MC, Arikan-Akdagli S, Bille J, Donnelly JP, et al. ESCMID* guideline for the diagnosis and management of Candida diseases 2012: diagnostic procedures. *Clin Microbiol Infect* 2012;18(Suppl. 7):9–18.
- Hope WW, Castagnola E, Groll AH, Roilides E, Akova M, Arendrup MC, et al. ESCMID* guideline for the diagnosis and management of Candida diseases 2012: prevention and management of invasive infections in neonates and children caused by *Candida* spp. *Clin Microbiol Infect* 2012;18(Suppl. 7):38–52.
- Lortholary O, Petrikos G, Akova M, Arendrup MC, Arikan-Akdagli S, Bassetti M, et al. ESCMID* guideline for the diagnosis and management of Candida diseases 2012: patients with HIV infection or AIDS. *Clin Microbiol Infect* 2012;18(Suppl. 7):68–77.
- Tortorano AM, Richardson M, Roilides E, van Diepeningen A, Caira M, Munoz P, et al. ESCMID and ECMM joint guidelines on diagnosis and management of hyalohyphomycosis: *Fusarium* spp., *Scedosporium* spp. and others. *Clin Microbiol Infect* 2014;20(Suppl. 3):27–46.
- Ullmann AJ, Akova M, Herbrecht R, Viscoli C, Arendrup MC, Arikan-Akdagli S, et al. ESCMID* guideline for the diagnosis and management of Candida diseases 2012: adults with haematological malignancies and after haematopoietic stem cell transplantation (HCT). *Clin Microbiol Infect* 2012;18(Suppl. 7):53–67.
- Ullmann AJ, Cornely OA, Donnelly JP, Akova M, Arendrup MC, Arikan-Akdagli S, et al. ESCMID* guideline for the diagnosis and management of Candida diseases 2012: developing European guidelines in clinical microbiology and infectious diseases. *Clin Microbiol Infect* 2012;18(Suppl. 7):1–8.
- Denning DW, Cadranal J, Beigelman-Aubry C, Ader F, Chakrabarti A, Blot S, et al. Chronic pulmonary aspergillosis: rationale and clinical guidelines for diagnosis and management. *Eur Respir J* 2016;47:45–68.
- Cornely OA, Cuenca-Estrella M, Meis JF, Ullmann AJ. European Society of Clinical Microbiology and Infectious Diseases (ESCMID) Fungal Infection Study Group (EFISG) and European Confederation of Medical Mycology (ECMM) 2013 joint guidelines on diagnosis and management of rare and emerging fungal diseases. *Clin Microbiol Infect* 2014;20(Suppl. 3):1–4.
- Marchiori E, Irion KL. Commentary on: "Analysis of initial and follow-up CT findings in patients with invasive pulmonary aspergillosis after solid organ transplantation". *Clin Radiol* 2012;67:1153–4.
- Bergeron A, Porcher R, Sulhian A, de Bazelaire C, Chagnon K, Raffoux E, et al. The strategy for the diagnosis of invasive pulmonary aspergillosis should depend on both the underlying condition and the leukocyte count of patients with hematologic malignancies. *Blood* 2012;119:1831–7. quiz 1956.
- Lim C, Seo JB, Park SY, Hwang HJ, Lee HJ, Lee SO, et al. Analysis of initial and follow-up CT findings in patients with invasive pulmonary aspergillosis after solid organ transplantation. *Clin Radiol* 2012;67:1179–86.
- Wingard JR. New approaches to invasive fungal infections in acute leukemia and hematopoietic stem cell transplant patients. *Best Pract Res Clin Haematol* 2007;20:99–107.
- Greene RE, Schlamm HT, Oestmann JW, Stark P, Durand C, Lortholary O, et al. Imaging findings in acute invasive pulmonary aspergillosis: clinical significance of the halo sign. *Clin Infect Dis* 2007;44:373–9.
- Greene R. The radiological spectrum of pulmonary aspergillosis. *Med Mycol* 2005;43(Suppl. 1):S147–54.
- Heussel CP, Kauczor HU, Heussel G, Fischer B, Mildenerberger P, Thelen M. Early detection of pneumonia in febrile neutropenic patients: use of thin-section CT. *Am J Roentgenol* 1997;169:1347–53.
- Heussel CP, Kauczor HU, Heussel GE, Fischer B, Begrich M, Mildenerberger P, et al. Pneumonia in febrile neutropenic patients and in bone marrow and blood stem-cell transplant recipients: use of high-resolution computed tomography. *J Clin Oncol* 1999;17:796–805.
- Caillot D, Casasnovas O, Bernard A, Couaillier JF, Durand C, Cuisenier B, et al. Improved management of invasive pulmonary aspergillosis in neutropenic patients using early thoracic computed tomographic scan and surgery. *J Clin Oncol* 1997;15:139–47.
- Caillot D, Mannone L, Cuisenier B, Couaillier JF. Role of early diagnosis and aggressive surgery in the management of invasive pulmonary aspergillosis in neutropenic patients. *Clin Microbiol Infect* 2001;7(Suppl. 2):54–61.
- Chamilos G, Marom EM, Lewis RE, Lionakis MS, Kontoyiannis DP. Predictors of pulmonary zygomycosis versus invasive pulmonary aspergillosis in patients with cancer. *Clin Infect Dis* 2005;41:60–6.
- Stanzani M, Battista G, Sassi C, Lewis RE, Tolomelli G, Clissa C, et al. Computed tomographic pulmonary angiography for diagnosis of invasive mold diseases in patients with hematological malignancies. *Clin Infect Dis* 2012;54:610–6.
- Stanzani M, Sassi C, Lewis RE, Tolomelli G, Bazzocchi A, Cavo M, et al. High resolution computed tomography angiography improves the radiographic diagnosis of invasive mold disease in patients with hematological malignancies. *Clin Infect Dis* 2015;60:1603–10.
- Sonnet S, Buitrago-Tellez CH, Tamm M, Christen S, Steinbrich W. Direct detection of angioinvasive pulmonary aspergillosis in immunosuppressed patients: preliminary results with high-resolution 16-MDCT angiography. *Am J Roentgenol* 2005;184:746–51.

- [27] Sodhi KS, Khandelwal N, Saxena AK, Singh M, Agarwal R, Bhatia A, et al. Rapid lung MRI in children with pulmonary infections: time to change our diagnostic algorithms. *J Magn Reson Imaging* 2016;43:1196–206.
- [28] Maschmeyer G, Carratala J, Buchheidt D, Hamprecht A, Heussel CP, Kahl C, et al. Diagnosis and antimicrobial therapy of lung infiltrates in febrile neutropenic patients (allogeneic SCT excluded): updated guidelines of the infectious diseases working party (AGIHO) of the German Society of Hematology and Medical Oncology (DGHO). *Ann Oncol* 2015;26:21–33.
- [29] Rieger C, Herzog P, Eibel R, Fiegl M, Ostermann H. Pulmonary MRI—a new approach for the evaluation of febrile neutropenic patients with malignancies. *Support Care Cancer* 2008;16:599–606.
- [30] Araz O, Karaman A, Ucar EY, Bilen Y, Durur Subasi I. DCE-MRI findings of invasive aspergillosis in patient with acute myeloid leukemia. *Clin Respir J* 2014;8:248–50.
- [31] Blum U, Windfuhr M, Buitrago-Tellez C, Sigmund G, Herbst EW, Langer M. Invasive pulmonary aspergillosis. MRI, CT, and plain radiographic findings and their contribution for early diagnosis. *Chest* 1994;106:1156–61.
- [32] Yan C, Tan X, Wei Q, Feng R, Li C, Wu Y, et al. Lung MRI of invasive fungal infection at 3 tesla: evaluation of five different pulse sequences and comparison with multidetector computed tomography (MDCT). *Eur Radiol* 2015;25:550–7.
- [33] Hot A, Maunoury C, Poiree S, Lanternier F, Viard JP, Loulergue P, et al. Diagnostic contribution of positron emission tomography with [¹⁸F]fluorodeoxyglucose for invasive fungal infections. *Clin Microbiol Infect* 2011;17:409–17.
- [34] Camus V, Edet-Sanson A, Bubenheim M, Hitzel A, Becker S, David M, et al. (1)(8)F-FDG-PET/CT imaging in patients with febrile neutropenia and haematological malignancies. *Anticancer Res* 2015;35:2999–3005.
- [35] Desoubreaux G, Bailly E, Chandener J. Diagnosis of invasive pulmonary aspergillosis: updates and recommendations. *Med Mal Infect* 2014;44:89–101.
- [36] Bruno C, Minniti S, Vassanelli A, Pozzi-Mucelli R. Comparison of CT features of aspergillus and bacterial pneumonia in severely neutropenic patients. *J Thorac Imag* 2007;22:160–5.
- [37] Nucci M, Nouer SA, Graziutti M, Kumar NS, Barlogie B, Anaissie E. Probable invasive aspergillosis without prespecified radiologic findings: proposal for inclusion of a new category of aspergillosis and implications for studying novel therapies. *Clin Infect Dis* 2010;51:1273–80.
- [38] Caillot D, Couaillier JF, Bernard A, Casasnovas O, Denning DW, Mannone L, et al. Increasing volume and changing characteristics of invasive pulmonary aspergillosis on sequential thoracic computed tomography scans in patients with neutropenia. *J Clin Oncol* 2001;19:253–9.
- [39] Kami M, Kishi Y, Hamaki T, Kawabata M, Kashima T, Masumoto T, et al. The value of the chest computed tomography halo sign in the diagnosis of invasive pulmonary aspergillosis. An autopsy-based retrospective study of 48 patients. *Mycoses* 2002;45:287–94.
- [40] Kuhlman JE, Fishman EK, Burch PA, Karp JE, Zerhouni EA, Siegelman SS. Invasive pulmonary aspergillosis in acute leukemia. The contribution of CT to early diagnosis and aggressive management. *Chest* 1987;92:95–9.
- [41] Franquet T, Gimenez A, Hidalgo A. Imaging of opportunistic fungal infections in immunocompromised patient. *Eur J Radiol* 2004;51:130–8.
- [42] Horger M, Hebart H, Einsele H, Lengerke C, Claussen CD, Vonthein R, et al. Initial CT manifestations of invasive pulmonary aspergillosis in 45 non-HIV immunocompromised patients: association with patient outcome? *Eur J Radiol* 2005;55:437–44.
- [43] Althoff Souza C, Muller NL, Marchiori E, Escuissato DL, Franquet T. Pulmonary invasive aspergillosis and candidiasis in immunocompromised patients: a comparative study of the high-resolution CT findings. *J Thorac Imag* 2006;21:184–9.
- [44] Horger M, Einsele H, Schumacher U, Wehrmann M, Hebart H, Lengerke C, et al. Invasive pulmonary aspergillosis: frequency and meaning of the “hypodense sign” on unenhanced CT. *Br J Radiol* 2005;78:697–703.
- [45] Marchiori E, Godoy MC, Zanetti G, Hochegger B, Rodrigues RS. The reversed halo sign. Another CT finding useful for distinguish invasive pulmonary aspergillosis and pulmonary lymphoma. *Eur J Radiol* 2011;79:e96–7.
- [46] Kojima R, Tateishi U, Kami M, Murashige N, Nannya Y, Kusumi E, et al. Chest computed tomography of late invasive aspergillosis after allogeneic hematopoietic stem cell transplantation. *Biol Blood Marrow Transpl* 2005;11:506–11.
- [47] Logan PM, Primack SL, Miller RR, Muller NL. Invasive aspergillosis of the airways: radiographic, CT, and pathologic findings. *Radiology* 1994;193:383–8.
- [48] Liss B, Vehreschild JJ, Bangard C, Maintz D, Frank K, Gronke S, et al. Our 2015 approach to invasive pulmonary aspergillosis. *Mycoses* 2015;58:375–82.
- [49] Azoulay E, Mokart D, Lambert J, Lemiale V, Rabbat A, Kouatlet A, et al. Diagnostic strategy for hematology and oncology patients with acute respiratory failure: randomized controlled trial. *Am J Respir Crit Care Med* 2010;182:1038–46.
- [50] Hummel M, Rudert S, Hof H, Hehlmann R, Buchheidt D. Diagnostic yield of bronchoscopy with bronchoalveolar lavage in febrile patients with hematologic malignancies and pulmonary infiltrates. *Ann Hematol* 2008;87:291–7.
- [51] Boersma WG, Erjavec Z, van der Werf TS, de Vries-Hosper HG, Gouw AS, Manson WL. Bronchoscopic diagnosis of pulmonary infiltrates in granulocytopenic patients with hematologic malignancies: BAL versus PSB and PBAL. *Resp Med* 2007;101:317–25.
- [52] Cornillet A, Camus C, Nimubona S, Gandemer V, Tattevin P, Belleguic C, et al. Comparison of epidemiological, clinical, and biological features of invasive aspergillosis in neutropenic and nonneutropenic patients: a 6-year survey. *Clin Infect Dis* 2006;43:577–84.
- [53] Jain P, Sandur S, Meli Y, Arroliga AC, Stoller JK, Mehta AC. Role of flexible bronchoscopy in immunocompromised patients with lung infiltrates. *Chest* 2004;125:712–22.
- [54] Peikert T, Rana S, Edell ES. Safety, diagnostic yield, and therapeutic implications of flexible bronchoscopy in patients with febrile neutropenia and pulmonary infiltrates. *Mayo Clinic Proc* 2005;80:1414–20.
- [55] Ramila E, Sureda A, Martino R, Santamaria A, Franquet T, Puzo C, et al. Bronchoscopy guided by high-resolution computed tomography for the diagnosis of pulmonary infections in patients with hematologic malignancies and normal plain chest X-ray. *Haematologica* 2000;85:961–6.
- [56] Becker MJ, Lugtenburg EJ, Cornelissen JJ, Van Der Schee C, Hoogsteden HC, De Marie S. Galactomannan detection in computerized tomography-based broncho-alveolar lavage fluid and serum in haematological patients at risk for invasive pulmonary aspergillosis. *Br J Haematol* 2003;121:448–57.
- [57] de Bazelaire C, Coffin A, Cohen-Zarade S, de Margerie-Mellon C, Scemama A, Sabatier F, et al. CT-guided biopsies in lung infections in patients with haematological malignancies. *Diagn Intervent Imaging* 2013;94:202–15.
- [58] Reinwald M, Spiess B, Heinz WJ, Heussel CP, Bertz H, Cornely OA, et al. *Aspergillus* PCR-based investigation of fresh tissue and effusion samples in patients with suspected invasive aspergillosis enhances diagnostic capabilities. *J Clin Microbiol* 2013;51:4178–85.
- [59] Gupta S, Sultenfuss M, Romaguera JE, Ensor J, Krishnamurthy S, Wallace MJ, et al. CT-guided percutaneous lung biopsies in patients with haematological malignancies and undiagnosed pulmonary lesions. *Hematol Oncol* 2010;28:75–81.
- [60] Shi JM, Cai Z, Huang H, Ye XJ, He JS, Xie WZ, et al. Role of CT-guided percutaneous lung biopsy in diagnosis of pulmonary fungal infection in patients with hematologic diseases. *Int J Hematol* 2009;89:624–7.
- [61] Lass-Flörl C, Resch G, Nachbaur D, Mayr A, Gastl G, Aubberger J, et al. The value of computed tomography-guided percutaneous lung biopsy for diagnosis of invasive fungal infection in immunocompromised patients. *Clin Infect Dis* 2007;45:e101–4.
- [62] Rickerts V, Mousset S, Lambrecht E, Tintelnot K, Schwerdtfeger R, Presterl E, et al. Comparison of histopathological analysis, culture, and polymerase chain reaction assays to detect invasive mold infections from biopsy specimens. *Clin Infect Dis* 2007;44:1078–83.
- [63] Carrafello G, Lagana D, Nosari AM, Guffanti C, Morra E, Recaldini C, et al. Utility of computed tomography (ct) and of fine needle aspiration biopsy (fnab) in early diagnosis of fungal pulmonary infections. Study of infections from filamentous fungi in haematologically immunodeficient patients. *La Radiologia Med* 2006;111:33–41.
- [64] Nosari A, Anghilieri M, Carrafello G, Guffanti C, Marbello L, Montillo M, et al. Utility of percutaneous lung biopsy for diagnosing filamentous fungal infections in hematologic malignancies. *Haematologica* 2003;88:1405–9.
- [65] Manhire A, Charig M, Clelland C, Gleeson F, Miller R, Moss H, et al. Guidelines for radiologically guided lung biopsy. *Thorax* 2003;58:920–36.
- [66] Georgiadou SP, Sampsonas FL, Rice D, Granger JM, Swisher S, Kontoyiannis DP. Open-lung biopsy in patients with undiagnosed lung lesions referred at a tertiary cancer center is safe and reveals noncancerous, noninfectious entities as the most common diagnoses. *Eur J Clin Microbiol Infect Dis* 2013;32:101–5.
- [67] Armenian SH, Hoffman JA, Butturini AM, Kapoor N, Mascarenhas L. Invasive diagnostic procedures for pulmonary infiltrates in pediatric hematopoietic stem cell transplant recipients. *Pediatr Transpl* 2007;11:736–42.
- [68] Zihlif M, Khanchandani G, Ahmed HP, Soubani AO. Surgical lung biopsy in patients with hematological malignancy or hematopoietic stem cell transplantation and unexplained pulmonary infiltrates: improved outcome with specific diagnosis. *Am J Hematol* 2005;78:94–9.
- [69] Wingard JR, Hiemenz JW, Jantz MA. How I manage pulmonary nodular lesions and nodular infiltrates in patients with hematologic malignancies or undergoing hematopoietic cell transplantation. *Blood* 2012;120:1791–800.
- [70] Choi YR, An JY, Kim MK, Han HS, Lee KH, Kim SW, et al. The diagnostic efficacy and safety of endobronchial ultrasound-guided transbronchial needle aspiration as an initial diagnostic tool. *Korean J Intern Med* 2013;28:660–7.
- [71] Casal RF, Adachi R, Jimenez CA, Sarkiss M, Morice RC, Eapen GA. Diagnosis of invasive aspergillus tracheobronchitis facilitated by endobronchial ultrasound-guided transbronchial needle aspiration: a case report. *J Med Case Rep* 2009;3:9290.
- [72] Aragaki-Nakahodo A, Benzaquen S, Kirschner M. Coinfection by *Nocardia beijingensis* and *Nocardia arthritidis* in an immunocompromised patient diagnosed by endobronchial ultrasound guided transbronchial needle aspiration (EBUS-TBNA). *Respir Med Case Rep* 2014;12:22–3.
- [73] They A, Espitalier F, Cassagnau E, Durand N, Malard O. Clinical features and outcome of sphenoid sinus aspergillosis: a retrospective series of 15 cases. *Eur Ann Otorhinolaryngol Head Neck Dis* 2012;129:179–84.
- [74] Miyamoto Y, Sakamoto Y, Ohuchi M, Tokunaga R, Shigaki H, Kurashige J, et al. Orbital apex syndrome caused by invasive aspergillosis as an adverse effect of systemic chemotherapy for metastatic colorectal cancer: a case report. *Anticancer Res* 2016;36:821–3.

- [75] Yuan L, Prayson RA. Optic nerve aspergillosis. *J Clin Neurosci* 2015;22:1191–3.
- [76] Marzolf G, Sabou M, Lannes B, Cotton F, Meyronet D, Galanaud D, et al. Magnetic resonance imaging of cerebral aspergillosis: imaging and pathological correlations. *PLoS One* 2016;11, e0152475.
- [77] Ashdown BC, Tien RD, Felsberg GJ. Aspergillosis of the brain and paranasal sinuses in immunocompromised patients: CT and MR imaging findings. *Am J Roentgenol* 1994;162:155–9.
- [78] DeLone DR, Goldstein RA, Petermann G, Salamat MS, Miles JM, Knechtle SJ, et al. Disseminated aspergillosis involving the brain: distribution and imaging characteristics. *Am J Neuroradiol* 1999;20:1597–604.
- [79] Guermazi A, Gluckman E, Tabti B, Miaux Y. Invasive central nervous system aspergillosis in bone marrow transplantation recipients: an overview. *Eur Radiol* 2003;13:377–88.
- [80] Rüchel R, Schaffrinski M. Versatile fluorescent staining of fungi in clinical specimens by using the optical brightener blankophor. *J Clin Microbiol* 1999;37:2694–6.
- [81] Fraczek MG, Kirwan MB, Moore CB, Morris J, Denning DW, Richardson MD. Volume dependency for culture of fungi from respiratory secretions and increased sensitivity of *Aspergillus* quantitative PCR. *Mycoses* 2014;57:69–78.
- [82] Maertens JA, Klont R, Masson C, Theunissen K, Meersseman W, Lagrou K, et al. Optimization of the cutoff value for the *Aspergillus* double-sandwich enzyme immunoassay. *Clin Infect Dis* 2007;44:1329–36.
- [83] Duarte RF, Sanchez-Ortega I, Cuesta I, Arnan M, Patino B, Fernandez de Sevilla A, et al. Serum galactomannan-based early detection of invasive aspergillosis in hematology patients receiving effective antimold prophylaxis. *Clin Infect Dis* 2014;59:1696–702.
- [84] Teering S, Verreth A, Peeters A, Van Regenmortel N, De Laet I, Schoonheydt K, et al. Prognostic value of serum galactomannan in mixed ICU patients: a retrospective observational study. *Anaesthesiol Intensive Ther* 2014;46:145–54.
- [85] Nouér SA, Nucci M, Kumar NS, Graziutti M, Barlogie B, Anaissie E. Earlier response assessment in invasive aspergillosis based on the kinetics of serum *Aspergillus* galactomannan: proposal for a new definition. *Clin Infect Dis* 2011;53:671–6.
- [86] D'Haese J, Theunissen K, Vermeulen E, Schoemans H, De Vlieger G, Lammerrin L, et al. Detection of galactomannan in bronchoalveolar lavage fluid samples of patients at risk for invasive pulmonary aspergillosis: analytical and clinical validity. *J Clin Microbiol* 2012;50:1258–63.
- [87] Pasqualotto AC, Xavier MO, Sanchez LB, de Oliveira Costa CD, Schio SM, Camargo SM, et al. Diagnosis of invasive aspergillosis in lung transplant recipients by detection of galactomannan in the bronchoalveolar lavage fluid. *Transplantation* 2010;90:306–11.
- [88] Luong ML, Clancy CJ, Vadnerkar A, Kwak EJ, Silveira FP, Wissel MC, et al. Comparison of an aspergillus real-time polymerase chain reaction assay with galactomannan testing of bronchoalveolar lavage fluid for the diagnosis of invasive pulmonary aspergillosis in lung transplant recipients. *Clin Infect Dis* 2011;52:1218–26.
- [89] Meersseman W, Lagrou K, Maertens J, Wilmer A, Hermans G, Vanderschueren S, et al. Galactomannan in bronchoalveolar lavage fluid: a tool for diagnosing aspergillosis in intensive care unit patients. *Am J Respir Crit Care Med* 2008;177:27–34.
- [90] Karageorgopoulos DE, Vouloumanou EK, Ntziora F, Michalopoulos A, Rafailidis PI, Falagas ME. β -d-glucan assay for the diagnosis of invasive fungal infections: a meta-analysis. *Clin Infect Dis* 2011;52:750–70.
- [91] Prattes J, Lackner M, Eigl S, Reischies F, Raggam RB, Koidl C, et al. Diagnostic accuracy of the aspergillus-specific bronchoalveolar lavage lateral-flow assay in haematological malignancy patients. *Mycoses* 2015;58:461–9.
- [92] Boch T, Reinwald M, Postina P, Cornely OA, Vehreschild JJ, Heussel CP, et al. Identification of invasive fungal diseases in immunocompromised patients by combining an aspergillus specific PCR with a multifungal DNA-microarray from primary clinical samples. *Mycoses* 2015;58:735–45.
- [93] Boch T, Spiess B, Cornely OA, Vehreschild JJ, Rath PM, Steinmann J, et al. Diagnosis of invasive fungal infections in haematological patients by combined use of galactomannan, 1,3- β -d-glucan, aspergillus PCR, multifungal DNA-microarray, and aspergillus azole resistance PCRs in blood and bronchoalveolar lavage samples: results of a prospective multicentre study. *Clin Microbiol Infect* 2016;22(10):862–8.
- [94] Springer J, Morton CO, Perry M, Heinz WJ, Paholcsek M, Alzheimer M, et al. Multicenter comparison of serum and whole-blood specimens for detection of aspergillus DNA in high-risk hematological patients. *J Clin Microbiol* 2013;51:1445–50.
- [95] Springer J, White PL, Hamilton S, Michel D, Barnes RA, Einsele H, et al. Comparison of performance characteristics of aspergillus PCR in testing a range of blood-based samples in accordance with international methodological recommendations. *J Clin Microbiol* 2016;54:705–11.
- [96] White PL, Wiederhold NP, Loeffler J, Najvar LK, Melchers W, Herrera M, et al. Comparison of nonculture blood-based tests for diagnosing invasive aspergillosis in an animal model. *J Clin Microbiol* 2016;54:960–6.
- [97] White PL, Barnes RA, Springer J, Klingspor L, Cuenca-Estrella M, Morton CO, et al. Clinical performance of aspergillus PCR for testing serum and plasma: a study by the European aspergillus PCR initiative. *J Clin Microbiol* 2015;53:2832–7.
- [98] Rogers TR, Morton CO, Springer J, Conneally E, Heinz W, Kenny C, et al. Combined real-time PCR and galactomannan surveillance improves diagnosis of invasive aspergillosis in high risk patients with haematological malignancies. *Br J Haematol* 2013;161:517–24.
- [99] Aguado JM, Vazquez L, Fernandez-Ruiz M, Villaescusa T, Ruiz-Camps I, Barba P, et al. Serum galactomannan versus a combination of galactomannan and polymerase chain reaction-based aspergillus DNA detection for early therapy of invasive aspergillosis in high-risk hematological patients: a randomized controlled trial. *Clin Infect Dis* 2015;60:405–14.
- [100] Vermeulen E, Lagrou K, Verweij PE. Azole resistance in *Aspergillus fumigatus*: a growing public health concern. *Curr Opin Infect Dis* 2013;26:493–500.
- [101] Chowdhary A, Kathuria S, Xu J, Meis JF. Emergence of azole-resistant *Aspergillus fumigatus* strains due to agricultural azole use creates an increasing threat to human health. *PLoS Pathogens* 2013;9, e1003633.
- [102] Koehler P, Hamprecht A, Bader O, Bekeredjian-Ding I, Buchheidt D, Doelken G, et al. Epidemiology of invasive aspergillosis and azole resistance in patients with acute leukaemia: the sepia study. *Int J Antimicrob Agents* 2017;49:218–23.
- [103] Van Der Linden JW, Warris A, Verweij PE. *Aspergillus* species intrinsically resistant to antifungal agents. *Med Mycol* 2011;49(Suppl. 1):S82–9.
- [104] Anderson JB. Evolution of antifungal-drug resistance: mechanisms and pathogen fitness. *Nat Rev Microbiol* 2005;3:547–56.
- [105] van der Linden JW, Arendrup MC, Warris A, Lagrou K, Pelloux H, Hauser PM, et al. Prospective multicenter international surveillance of azole resistance in *Aspergillus fumigatus*. *Emerg Infect Dis* 2015;21:1041–4.
- [106] Chowdhary A, Sharma C, van den Boom M, Yntema JB, Hagen F, Verweij PE, et al. Multi-azole-resistant *Aspergillus fumigatus* in the environment in Tanzania. *J Antimicrob Chemother* 2014;69:2979–83.
- [107] Verweij PE, Chowdhary A, Melchers WJ, Meis JF. Azole resistance in *Aspergillus fumigatus*: can we retain the clinical use of mold-active antifungal azoles? *Clin Infect Dis* 2016;62:362–8.
- [108] Ozmerdiven GE, Ak S, Ener B, Agca H, Cilo BD, Tunca B, et al. First determination of azole resistance in *Aspergillus fumigatus* strains carrying the TR34/L98H mutations in Turkey. *J Infect Chemother* 2015;21:581–6.
- [109] Astvad KM, Jensen RH, Hassan TM, Mathiasen EG, Thomsen GM, Pedersen UG, et al. First detection of TR46/Y121F/T289A and TR34/L98H alterations in *Aspergillus fumigatus* isolates from azole-naïve patients in Denmark despite negative findings in the environment. *Antimicrob Agents Chemother* 2014;58:5096–101.
- [110] Verweij PE, Snelders E, Kema GH, Mellado E, Melchers WJ. Azole resistance in *Aspergillus fumigatus*: a side-effect of environmental fungicide use? *Lancet Infect Dis* 2009;9:789–95.
- [111] Stensvold CR, Nistrup Jørgensen L, Maiken CA. Azole-resistant invasive aspergillosis: relationship to agriculture. *Curr Fungal Infect Rep* 2012;6:178–91.
- [112] Bowyer P, Denning DW. Environmental fungicides and triazole resistance in aspergillus. *Pest Manag Sci* 2014;70:173–8.
- [113] van der Linden JW, Snelders E, Kampinga GA, Arends JP, Debets-Ossenkopp YJ, Haas PJ, et al. Clinical implications of azole resistance in *Aspergillus fumigatus*, The Netherlands, 2007–2009. *Emerg Infect Dis* 2011;17:1846–54.
- [114] van der Linden JW, Camps SM, Kampinga GA, Arends JP, Debets-Ossenkopp YJ, Haas PJ, et al. Aspergillosis due to voriconazole highly resistant *Aspergillus fumigatus* and recovery of genetically related resistant isolates from domiciles. *Clin Infect Dis* 2013;57:513–20.
- [115] Howard SJ, Cerar D, Anderson MJ, Albarrag A, Fisher MC, Pasqualotto AC, et al. Frequency and evolution of azole resistance in *Aspergillus fumigatus* associated with treatment failure. *Emerg Infect Dis* 2009;15:1068–76.
- [116] Camps SM, van der Linden JW, Li Y, Kuijper EJ, van Dissel JT, Verweij PE, et al. Rapid induction of multiple resistance mechanisms in *Aspergillus fumigatus* during azole therapy: a case study and review of the literature. *Antimicrob Agents Chemother* 2012;56:10–6.
- [117] Ahmad S, Joseph L, Hagen F, Meis JF, Khan Z. Concomitant occurrence of itraconazole-resistant and -susceptible strains of *Aspergillus fumigatus* in routine cultures. *J Antimicrob Chemother* 2015;70:412–5.
- [118] Arendrup MC, Verweij PE, Mouton JW, Lagrou K, Meletiadi S. Multicentre validation of 4-well azole agar plates as a screening method for detection of clinically relevant azole-resistant *Aspergillus fumigatus*. *J Antimicrob Chemother* 2017;72:3325–33.
- [119] Andes D, Pascual A, Marchetti O. Antifungal therapeutic drug monitoring: established and emerging indications. *Antimicrob Agents Chemother* 2009;53:24–34.
- [120] Tricot G, Joosten E, Boogaerts MA, Vande-Pitte J, Cauwenbergh G. Ketocozazole vs. Itraconazole for antifungal prophylaxis in patients with severe granulocytopenia: preliminary results of two nonrandomized studies. *Rev Infect Dis* 1987;9(Suppl. 1):S94–9.
- [121] Morgenstern GR, Prentice AG, Grant Prentice H, Ropner JE, Schey SA, Warnock DW, et al. A randomized controlled trial of itraconazole versus fluconazole for the prevention of fungal infections in patients with haematological malignancies. *Br J Haematol* 1999;105:901–11.
- [122] Glasmacher A, Hahn C, Molitor E, Marklein G, Sauerbruch T, Schmidt-Wolf I. Itraconazole trough concentrations in antifungal prophylaxis with six different dosing regimens using hydroxypropyl- β -cyclodextrin oral solution or coated-pellet capsules. *Mycoses* 1999;42:591–600.

- [123] Glasmacher A, Hahn C, Leutner C, Molitor E, Wardelmann E, Losem C, et al. Breakthrough invasive fungal infections in neutropenic patients after prophylaxis with itraconazole. *Mycoses* 1999;42:443–51.
- [124] Glasmacher A, Prentice A, Gorschlüter M, Engelhart S, Hahn C, Djulbegovic B, et al. Itraconazole prevents invasive fungal infections in neutropenic patients treated for hematologic malignancies: evidence from a meta-analysis of 3,597 patients. *J Clin Oncol* 2003;21:4615–26.
- [125] Boogaerts MA, Verhoef GE, Zachee P, Demuyneck H, Verbist L, De Beule K. Antifungal prophylaxis with itraconazole in prolonged neutropenia: correlation with plasma levels. *Mycoses* 1989;32(Suppl. 1):103–8.
- [126] Denning DW, Lee JY, Hostetler JS, Pappas P, Kauffman CA, Dewshup DH, et al. Niasid mycoses study group multicenter trial of oral itraconazole therapy for invasive aspergillosis. *Am J Med* 1994;97:135–44.
- [127] Lestner JM, Roberts SA, Moore CB, Howard SJ, Denning DW, Hope WW. Toxicodynamics of itraconazole: implications for therapeutic drug monitoring. *Clin Infect Dis* 2009;49:928–30.
- [128] Pascual A, Csajka C, Buclin T, Bolay S, Bille J, Calandra T, et al. Challenging recommended oral and intravenous voriconazole doses for improved efficacy and safety: population pharmacokinetics-based analysis of adult patients with invasive fungal infections. *Clin Infect Dis* 2012;55:381–90.
- [129] Pascual A, Calandra T, Bolay S, Buclin T, Bille J, Marchetti O. Voriconazole therapeutic drug monitoring in patients with invasive mycoses improves efficacy and safety outcomes. *Clin Infect Dis* 2008;46:201–11.
- [130] Park WB, Kim N-H, Kim K-H, Lee SH, Nam W-S, Yoon SH, et al. The effect of therapeutic drug monitoring on safety and efficacy of voriconazole in invasive fungal infections: a randomized controlled trial. *Clin Infect Dis* 2012;55:1080–7.
- [131] Troke PF, Hockey HP, Hope WW. Observational study of the clinical efficacy of voriconazole and its relationship to plasma concentrations in patients. *Antimicrob Agents Chemother* 2011;55:4782–8.
- [132] Trifilio S, Singhal S, Williams S, Frankfurt O, Gordon L, Evens A, et al. Breakthrough fungal infections after allogeneic hematopoietic stem cell transplantation in patients on prophylactic voriconazole. *Bone Marrow Transpl* 2007;40:451–6.
- [133] Dolton MJ, Ray JE, Chen SCA, Ng K, Pont LG, McLachlan AJ. Multicenter study of voriconazole pharmacokinetics and therapeutic drug monitoring. *Antimicrob Agents Chemother* 2012;56:4793–9.
- [134] Neely M, Margol A, Fu X, van Guilder M, Bayard D, Schumitzky A, et al. Achieving target voriconazole concentrations more accurately in children and adolescents. *Antimicrob Agents Chemother* 2015;59:3090–7.
- [135] Friberg LE, Ravva P, Karlsson MO, Liu P. Integrated population pharmacokinetic analysis of voriconazole in children, adolescents and adults. *Antimicrob Agents Chemother* 2012;56:3032–42.
- [136] Jang SH, Colangelo PM, Gobburu JVS. Exposure–response of posaconazole used for prophylaxis against invasive fungal infections: evaluating the need to adjust doses based on drug concentrations in plasma. *Clin Pharmacol Therapeut* 2010;88:115–9.
- [137] Cornely OA, Ullmann AJ. Lack of evidence for exposure-response relationship in the use of posaconazole as prophylaxis against invasive fungal infections. *Clin Pharmacol Therapeut* 2011;89:351–2.
- [138] Walsh TJ, Raad I, Patterson TF, Chandrasekar P, Donowitz GR, Graybill R, et al. Treatment of invasive aspergillosis with posaconazole in patients who are refractory to or intolerant of conventional therapy: an externally controlled trial. *Clin Infect Dis* 2007;44:2–12.
- [139] European Medicine A. Assessment report: Noxafil. 2014.
- [140] Cornely OA, Robertson MN, Haider S, Grigg A, Geddes M, Aoun M, et al. Pharmacokinetics and safety results from the phase 3 randomized, open-label, study of intravenous posaconazole in patients at risk of invasive fungal disease. *J Antimicrob Chemother* 2017;72(12):3406–13.
- [141] Cornely OA, Duarte RF, Haider S, Chandrasekar P, Helfgott D, Jimenez JL, et al. Phase 3 pharmacokinetics and safety study of a posaconazole tablet formulation in patients at risk for invasive fungal disease. *J Antimicrob Chemother* 2016;71:1747.
- [142] Bowden R, Chandrasekar P, White MH, Li X, Pietrelli L, Gurwith M, et al. A double-blind, randomized, controlled trial of amphotericin B colloidal dispersion versus amphotericin B for treatment of invasive aspergillosis in immunocompromised patients. *Clin Infect Dis* 2002;35:359–66.
- [143] Stamm AM, Diasio RB, Dismukes WE, Shadomy S, Cloud GA, Bowles CA, et al. Toxicity of amphotericin B plus flucytosine in 194 patients with cryptococcal meningitis. *Am J Med* 1987;83:236–42.
- [144] Pasqualotto AC, Howard SJ, Moore CB, Denning DW. Flucytosine therapeutic monitoring: 15 years experience from the UK. *J Antimicrob Chemother* 2007;59:791–3.
- [145] Walsh TJ, Dixon DM. Nosocomial aspergillosis: environmental microbiology, hospital epidemiology, diagnosis and treatment. *Eur J Epidemiol* 1989;5:131–42.
- [146] Goodley JM, Clayton YM, Hay RJ. Environmental sampling for aspergilli during building construction on a hospital site. *J Hosp Infect* 1994;26:27–35.
- [147] Perraud M, Piens MA, Nicoloyannis N, Girard P, Sepetjan M, Garin JP. Invasive nosocomial pulmonary aspergillosis: risk factors and hospital building works. *Epidemiol Infect* 1987;99:407–12.
- [148] Opal SM, Asp AA, Cannady Jr PB, Morse PL, Burton LJ, Hammer 2nd PG. Efficacy of infection control measures during a nosocomial outbreak of disseminated aspergillosis associated with hospital construction. *J Infect Dis* 1986;153:634–7.
- [149] Weems Jr JJ, Davis BJ, Tablan OC, Kaufman L, Martone WJ. Construction activity: an independent risk factor for invasive aspergillosis and zygomycosis in patients with hematologic malignancy. *Infect Control* 1987;8:71–5.
- [150] Meheust D, Le Cann P, Reboux G, Millon L, Gangneux JP. Indoor fungal contamination: health risks and measurement methods in hospitals, homes and workplaces. *Crit Rev Microbiol* 2014;40:248–60.
- [151] Sherertz RJ, Belani A, Kramer BS, Eifenbein GJ, Weiner RS, Sullivan ML, et al. Impact of air filtration on nosocomial aspergillus infections. Unique risk of bone marrow transplant recipients. *Am J Med* 1987;83:709–18.
- [152] Barnes RA, Rogers TR. Control of an outbreak of nosocomial aspergillosis by laminar air-flow isolation. *J Hosp Infect* 1989;14:89–94.
- [153] Thio CL, Smith D, Merz WG, Streifel AJ, Bova G, Gay L, et al. Refinements of environmental assessment during an outbreak investigation of invasive aspergillosis in a leukemia and bone marrow transplant unit. *Infect Control Hosp Epidemiol* 2000;21:18–23.
- [154] Hahn T, Cummings KM, Michalek AM, Lipman BJ, Segal BH, McCarthy Jr PL. Efficacy of high-efficiency particulate air filtration in preventing aspergillosis in immunocompromised patients with hematologic malignancies. *Infect Control Hosp Epidemiol* 2002;23:525–31.
- [155] Maschmeyer G, Neuburger S, Fritz L, Bohme A, Penack O, Schwerdtfeger R, et al. A prospective, randomised study on the use of well-fitting masks for prevention of invasive aspergillosis in high-risk patients. *Ann Oncol* 2009;20:1560–4.
- [156] Anaissie EJ, Stratton SL, Dignani MC, Summerbell RC, Rex JH, Monson TP, et al. Pathogenic *Aspergillus* species recovered from a hospital water system: a 3-year prospective study. *Clin Infect Dis* 2002;34:780–9.
- [157] Anaissie EJ, Penzak SR, Dignani MC. The hospital water supply as a source of nosocomial infections: a plea for action. *Archiv Intern Med* 2002;162:1483–92.
- [158] Anaissie EJ, Stratton SL, Dignani MC, Lee CK, Mahfouz TH, Rex JH, et al. Cleaning patient shower facilities: a novel approach to reducing patient exposure to aerosolized aspergillus species and other opportunistic molds. *Clin Infect Dis* 2002;35:E86–8.
- [159] Anaissie EJ, Stratton SL, Dignani MC, Lee CK, Summerbell RC, Rex JH, et al. Pathogenic molds (including *Aspergillus* species) in hospital water distribution systems: a 3-year prospective study and clinical implications for patients with hematologic malignancies. *Blood* 2003;101:2542–6.
- [160] Lee LD, Hachem RY, Berkheiser M, Hackett B, Jiang Y, Raad II. Hospital environment and invasive aspergillosis in patients with hematologic malignancy. *Am J Infect Control* 2012;40:247–9.
- [161] Mahieu LM, De Dooy JJ, Van Laer FA, Jansens H, Ieven MM. A prospective study on factors influencing aspergillus spore load in the air during renovation works in a neonatal intensive care unit. *J Hosp Infect* 2000;45:191–7 [Record as supplied by publisher].
- [162] Rüping MJ, Gerlach S, Fischer G, Lass-Flörl C, Hellmich M, Vehreschild JJ, et al. Environmental and clinical epidemiology of *Aspergillus terreus*: data from a prospective surveillance study. *J Hosp Infect* 2011;78:226–30.
- [163] Chamilo G, Luna M, Lewis RE, Bodey GP, Chemaly R, Tarrand JJ, et al. Invasive fungal infections in patients with hematologic malignancies in a tertiary care cancer center: an autopsy study over a 15-year period (1989–2003). *Haematologica* 2006;91:986–9.
- [164] Sinko J, Csomor J, Nikolova R, Lueff S, Krivan G, Remenyi P, et al. Invasive fungal disease in allogeneic hematopoietic stem cell transplant recipients: an autopsy-driven survey. *Transpl Infect Dis* 2008;10:106–9.
- [165] Lewis RE, Cahyame-Zuniga L, Leventakos K, Chamilo G, Ben-Ami R, Tamboli P, et al. Epidemiology and sites of involvement of invasive fungal infections in patients with haematological malignancies: a 20-year autopsy study. *Mycoses* 2013;56:638–45.
- [166] Marr KA, Carter RA, Crippa F, Wald A, Corey L. Epidemiology and outcome of mold infections in hematopoietic stem cell transplant recipients. *Clin Infect Dis* 2002;34:909–17.
- [167] Wald A, Leisenring W, van Burik JA, Bowden RA. Epidemiology of aspergillus infections in a large cohort of patients undergoing bone marrow transplantation. *J Infect Dis* 1997;175:1459–66.
- [168] Neofytos D, Horn D, Anaissie E, Steinbach W, Olyaei A, Fishman J, et al. Epidemiology and outcome of invasive fungal infection in adult hematopoietic stem cell transplant recipients: analysis of multicenter prospective antifungal therapy (path) alliance registry. *Clin Infect Dis* 2009;48:265–73.
- [169] De Pauw B, Walsh TJ, Donnelly JP, Stevens DA, Edwards JE, Galandra T, et al. Revised definitions of invasive fungal disease from the European Organization for Research and Treatment of Cancer/Invasive Fungal Infections Cooperative Group and the National Institute of Allergy and Infectious Diseases Mycoses Study Group (EORTC/MSG) consensus group. *Clin Infect Dis* 2008;46:1813–21.
- [170] Herbrecht R, Denning DW, Patterson TF, Bennett JE, Greene RE, Oestmann JW, et al. Voriconazole versus amphotericin B for primary therapy of invasive aspergillosis. *N Engl J Med* 2002;347:408–15.
- [171] Cornely OA, Maertens J, Bresnik M, Ebrahimi R, Ullmann AJ, Bouza E, et al. Liposomal amphotericin B as initial therapy for invasive mold infection: a randomized trial comparing a high-loading dose regimen with standard dosing (ambload trial). *Clin Infect Dis* 2007;44:1289–97.
- [172] Marr KA, Schlamm HT, Herbrecht R, Rottinghaus ST, Bow EJ, Cornely OA, et al. Combination antifungal therapy for invasive aspergillosis: a randomized trial. *Ann Intern Med* 2015;162:81–9.

- [173] Maertens JA, Raad II, Marr KA, Patterson TF, Kontoyiannis DP, Cornely OA, et al. Isavuconazole versus voriconazole for primary treatment of invasive mould disease caused by *Aspergillus* and other filamentous fungi (secure): a phase 3, randomised-controlled, non-inferiority trial. *Lancet* 2016;387:760–9.
- [174] Ofran Y, Avivi I, Oliven A, Oren I, Zuckerman T, Bonstein L, et al. Granulocyte transfusions for neutropenic patients with life-threatening infections: a single centre experience in 47 patients, who received 348 granulocyte transfusions. *Vox Sang* 2007;93:363–9.
- [175] Safdar A, Rodriguez GH, Lichtiger B, Dickey BF, Kontoyiannis DP, Freireich EJ, et al. Recombinant interferon γ 1b immune enhancement in 20 patients with hematologic malignancies and systemic opportunistic infections treated with donor granulocyte transfusions. *Cancer* 2006;106:2664–71.
- [176] Sachs UJ, Reiter A, Walter T, Bein G, Woessmann W. Safety and efficacy of therapeutic early onset granulocyte transfusions in pediatric patients with neutropenia and severe infections. *Transfusion* 2006;46:1909–14.
- [177] Dignani MC, Rex JH, Chan KW, Dow G, deMagalhaes-Silverman M, Maddox A, et al. Immunomodulation with interferon-gamma and colony-stimulating factors for refractory fungal infections in patients with leukemia. *Cancer* 2005;104:199–204.
- [178] Lee JJ, Chung JJ, Park MR, Kook H, Hwang TJ, Ryang DW, et al. Clinical efficacy of granulocyte transfusion therapy in patients with neutropenia-related infections. *Leukemia* 2001;15:203–7.
- [179] Dignani MC, Anaissie EJ, Hester JP, O'Brien S, Vartivarian SE, Rex JH, et al. Treatment of neutropenia-related fungal infections with granulocyte colony-stimulating factor-elicited white blood cell transfusions: a pilot study. *Leukemia* 1997;11:1621–30.
- [180] Massey E, Paulus U, Doree C, Stanworth S. Granulocyte transfusions for preventing infections in patients with neutropenia or neutrophil dysfunction. *Cochrane Database Syst Rev* 2009, CD005341.
- [181] Pizzo PA, Robichaud KJ, Gill FA, Witebsky FG. Empiric antibiotic and antifungal therapy for cancer patients with prolonged fever and granulocytopenia. *Am J Med* 1982;72:101–11.
- [182] Pizzo PA, Robichaud KJ, Wesley R, Commers JR. Fever in the pediatric and young adult patient with cancer. A prospective study of 1001 episodes. *Medicine (Balt)* 1982;61:153–65.
- [183] EORTC International Antimicrobial Therapy Cooperative Group. Empiric antifungal therapy in febrile granulocytopenic patients. *Am J Med* 1989;86:668–72.
- [184] Goldberg E, Gafter-Gvili A, Robenshtok E, Leibovici L, Paul M. Empirical antifungal therapy for patients with neutropenia and persistent fever: systematic review and meta-analysis. *Eur J Cancer* 2008;44:2192–203.
- [185] Cordonnier C, Pautas C, Maury S, Vekhoff A, Farhat H, Suarez F, et al. Empirical versus preemptive antifungal therapy for high-risk, febrile, neutropenic patients: a randomized, controlled trial. *Clin Infect Dis* 2009;48:1042–51.
- [186] Girmenia C, Micozzi A, Gentile G, Santilli S, Arleo E, Cardarelli L, et al. Clinically driven diagnostic antifungal approach in neutropenic patients: a prospective feasibility study. *J Clin Oncol* 2010;28:667–74.
- [187] Pagano L, Cairá M, Nosari A, Cattaneo C, Fanci R, Bonini A, et al. The use and efficacy of empirical versus pre-emptive therapy in the management of fungal infections: the hema e-chart project. *Haematologica* 2011;96:1366–70.
- [188] Walsh TJ, Teppler H, Donowitz GR, Maertens JA, Baden LR, Dmoszynska A, et al. Caspofungin versus liposomal amphotericin B for empirical antifungal therapy in patients with persistent fever and neutropenia. *N Engl J Med* 2004;351:1391–402.
- [189] Walsh TJ, Finberg RW, Arndt C, Hiemenz J, Schwartz C, Bodensteiner D, et al. Liposomal amphotericin B for empirical therapy in patients with persistent fever and neutropenia. National institute of allergy and infectious diseases mycoses study group. *N Engl J Med* 1999;340:764–71.
- [190] Walsh TJ, Pappas P, Winston DJ, Lazarus HM, Petersen F, Raffalli J, et al. Voriconazole compared with liposomal amphotericin B for empirical antifungal therapy in patients with neutropenia and persistent fever. *N Engl J Med* 2002;346:225–34.
- [191] White PL, Parr C, Thornton C, Barnes RA. Evaluation of real-time PCR, galactomannan enzyme-linked immunosorbent assay (ELISA), and a novel lateral-flow device for diagnosis of invasive aspergillosis. *J Clin Microbiol* 2013;51:1510–6.
- [192] White PL, Wingard JR, Bretagne S, Liffler J, Patterson TF, Slavin MA, et al. *Aspergillus* polymerase chain reaction: systematic review of evidence for clinical use in comparison with antigen testing. *Clin Infect Dis* 2015;61:1293–303.
- [193] Liss B, Cornely OA, Hoffmann D, Dimitriou V, Wisplinghoff H. 1,3- β -d-glucan contamination of common antimicrobials—authors' response. *J Antimicrob Chemother* 2016;71:2997–9.
- [194] Liss B, Cornely OA, Hoffmann D, Dimitriou V, Wisplinghoff H. 1,3- β -d-glucan contamination of common antimicrobials. *J Antimicrob Chemother* 2016;71:913–5.
- [195] Liss B, Cornely OA, Hoffmann D, Dimitriou V, Wisplinghoff H. 1,3- β -d-glucan concentrations in blood products predict false positive post-transfusion results. *Mycoses* 2016;59:39–42.
- [196] Hammarstrom H, Kondori N, Friman V, Wenneras C. How to interpret serum levels of β -glucan for the diagnosis of invasive fungal infections in adult high-risk hematology patients: optimal cut-off levels and confounding factors. *Eur J Clin Microbiol Infect Dis* 2015;34:917–25.
- [197] Bouza E, Guinea J, Pelaez T, Perez-Molina J, Alcalá L, Muñoz P. Workload due to *Aspergillus fumigatus* and significance of the organism in the microbiology laboratory of a general hospital. *J Clin Microbiol* 2005;43:2075–9.
- [198] Montagna MT, Lovero G, Coretti C, Martinelli D, Delia M, De Giglio O, et al. Simiff study: Italian fungal registry of mold infections in hematological and non-hematological patients. *Infection* 2014;42:141–51.
- [199] Garcia-Vidal C, Peghin M, Cervera C, Gudiol C, Ruiz-Camps I, Moreno A, et al. Causes of death in a contemporary cohort of patients with invasive aspergillosis. *PLoS One* 2015;10, e0120370.
- [200] Vena A, Muñoz P, Pelaez T, Guinea J, Valerio M, Bouza E. Non-construction related *Aspergillus* outbreak in non-hematological patients related to high concentrations of airborne spores in non-hepa filtered areas. *ID week, San Diego, CA*. 2015. October 7–11.
- [201] Ruiz-Camps I, Aguado JM, Almirante B, Bouza E, Ferrer Barbera C, Len O, et al. Recommendations of the Spanish Society of Infectious Diseases and Clinical Microbiology (SEIMC) on the prevention of invasive fungal infection due to filamentous fungi. *Enferm Infecc Microbiol Clin* 2010;28. 172 e171–172 e121.
- [202] Guinea J, Pelaez T, Alcalá L, Bouza E. Outdoor environmental levels of *Aspergillus* spp. conidia over a wide geographical area. *Med Mycol* 2006;44:349–56.
- [203] Pelaez T, Muñoz P, Guinea J, Valerio M, Giannella M, Klaassen CH, et al. Outbreak of invasive aspergillosis after major heart surgery caused by spores in the air of the intensive care unit. *Clin Infect Dis* 2012;54:e24–31.
- [204] Muñoz P, Guinea J, Pelaez T, Duran C, Blanco JL, Bouza E. Nosocomial invasive aspergillosis in a heart transplant patient acquired during a break in the hepa air filtration system. *Transpl Infect Dis* 2004;6:50–4.
- [205] Tang HJ, Liu WL, Chang TC, Li MC, Ko WC, Wu CJ, et al. Multiple brain abscesses due to *Aspergillus fumigatus* in a patient with liver cirrhosis: a case report. *Medicine (Balt)* 2016;95, e2813.
- [206] Pilms B, Puel A, Lortholary O, Lantermier F. New clinical phenotypes of fungal infections in special hosts. *Clin Microbiol Infect* 2016;22(8):681–7.
- [207] Falcone M, Concia E, Iori I, Lo Cascio G, Mazzone A, Pea F, et al. Identification and management of invasive mycoses in internal medicine: a road-map for physicians. *Intern Emerg Med* 2014;9:501–11.
- [208] Peghin M, Ruiz-Camps I, Garcia-Vidal C, Cervera C, Andreu J, Martin M, et al. Unusual forms of subacute invasive pulmonary aspergillosis in patients with solid tumors. *J Infect* 2014;69:387–95.
- [209] Pappas PG, Alexander BD, Andes DR, Hadley S, Kauffman CA, Freifeld A, et al. Invasive fungal infections among organ transplant recipients: results of the transplant-associated infection surveillance network (Transnet). *Clin Infect Dis* 2010;50:1101–11.
- [210] Gavalda J, Len O, San Juan R, Aguado JM, Fortun J, Lumbrales C, et al. Risk factors for invasive aspergillosis in solid-organ transplant recipients: a case-control study. *Clin Infect Dis* 2005;41:52–9.
- [211] Singh N, Husain S, Practice ASTIDCo. Aspergillosis in solid organ transplantation. *Am J Transpl* 2013;13(Suppl. 4):228–41.
- [212] Singh N, Limaye AP, Forrest G, Safdar N, Muñoz P, Pursell K, et al. Late-onset invasive aspergillosis in organ transplant recipients in the current era. *Med Mycol* 2006;44:445–9.
- [213] Gavalda J, Meije Y, Fortun J, Roilides E, Saliba F, Lortholary O, et al. Invasive fungal infections in solid organ transplant recipients. *Clin Microbiol Infect* 2014;20(Suppl. 7):27–48.
- [214] Muñoz P, Ceron I, Valerio M, Palomo J, Villa A, Eworo A, et al. Invasive aspergillosis among heart transplant recipients: a 24-year perspective. *J Heart Lung Transpl* 2014;33:278–88.
- [215] Muñoz P, Valerio M, Palomo J, Giannella M, Yanez JF, Desco M, et al. Targeted antifungal prophylaxis in heart transplant recipients. *Transplantation* 2013;96:664–9.
- [216] Barchiesi F, Mazzocato S, Mazzanti S, Gesuita R, Skrami E, Fiorentini A, et al. Invasive aspergillosis in liver transplant recipients: epidemiology, clinical characteristics, treatment, and outcomes in 116 cases. *Liver Transpl* 2015;21:204–12.
- [217] Winston DJ, Limaye AP, Pelletier S, Safdar N, Morris MI, Meneses K, et al. Randomized, double-blind trial of anidulafungin versus fluconazole for prophylaxis of invasive fungal infections in high-risk liver transplant recipients. *Am J Transpl* 2014;14:2758–64.
- [218] Lichtenstern C, Hochreiter M, Zehnter VD, Brenner T, Hofer S, Mieth M, et al. Pretransplant model for end stage liver disease score predicts posttransplant incidence of fungal infections after liver transplantation. *Mycoses* 2013;56:350–7.
- [219] Ohkubo T, Sugawara Y, Takayama T, Kokudo N, Makuuchi M. The risk factors of fungal infection in living-donor liver transplantations. *J Hepatobiliary Pancreat Sci* 2012;19:382–8.
- [220] San-Juan R, Aguado JM, Lumbrales C, Fortun J, Len O, Muñoz P, et al. Universal prophylaxis with fluconazole for the prevention of early invasive fungal infection in low-risk liver transplant recipients. *Transplantation* 2011;92:346–50.
- [221] Singh N, Wagener MM, Cacciarelli TV, Levitsky J. Antifungal management practices in liver transplant recipients. *Am J Transpl* 2008;8:426–31.
- [222] Osawa M, Ito Y, Hirai T, Isozumi R, Takakura S, Fujimoto Y, et al. Risk factors for invasive aspergillosis in living donor liver transplant recipients. *Liver Transpl* 2007;13:566–70.

- [223] Pappas PG, Andes D, Schuster M, Hadley S, Rabkin J, Merion RM, et al. Invasive fungal infections in low-risk liver transplant recipients: a multi-center prospective observational study. *Am J Transpl* 2006;6:386–91.
- [224] Fortun J, Martin-Davila P, Moreno S, De Vicente E, Nuno J, Candelas A, et al. Risk factors for invasive aspergillosis in liver transplant recipients. *Liver Transpl* 2002;8:1065–70.
- [225] Singh N, Husain S. Aspergillus infections after lung transplantation: clinical differences in type of transplant and implications for management. *J Heart Lung Transpl* 2003;22:258–66.
- [226] Weigt SS, Elashoff RM, Huang C, Ardehali A, Gregson AL, Kubak B, et al. Aspergillus colonization of the lung allograft is a risk factor for bronchiolitis obliterans syndrome. *Am J Transpl* 2009;9:1903–11.
- [227] Geltner C, Lass-Flörl C. Invasive pulmonary aspergillosis in organ transplants—focus on lung transplants. *Respir Investig* 2016;54:76–84.
- [228] Lopez-Medrano F, Silva JT, Fernandez-Ruiz M, Carver PL, van Delden C, Merino E, et al. Risk factors associated with early invasive pulmonary aspergillosis in kidney transplant recipients: results from a multinational matched case–control study. *Am J Transpl* 2016;16:2148–57.
- [229] Gustafson TL, Schaffner W, Lavelly GB, Stratton CW, Johnson HK, Hutcheson Jr RH. Invasive aspergillosis in renal transplant recipients: correlation with corticosteroid therapy. *J Infect Dis* 1983;148:230–8.
- [230] Wojtowicz A, Gresnigt MS, Lecompte T, Bibert S, Manuel O, Joosten LA, et al. IL1B and DEFB1 polymorphisms increase susceptibility to invasive mold infection after solid-organ transplantation. *J Infect Dis* 2015;211:1646–57.
- [231] Wojtowicz A, Lecompte TD, Bibert S, Manuel O, Rueger S, Berger C, et al. Ptx3 polymorphisms and invasive mold infections after solid organ transplant. *Clin Infect Dis* 2015;61:619–22.
- [232] Denis B, Guiguet M, de Castro N, Mechai F, Revest M, Melica G, et al. Relevance of EORTC criteria for the diagnosis of invasive aspergillosis in HIV-infected patients, and survival trends over a 20-year period in France. *Clin Infect Dis* 2015;61:1273–80.
- [233] Libanore M, Prini E, Mazzetti M, Barchi E, Raise E, Gritti FM, et al. Invasive aspergillosis in Italian AIDS patients. *Infection* 2002;30:341–5.
- [234] Moreno A, Perez-Elias M, Casado J, Navas E, Pintado V, Fortun J, et al. Role of antiretroviral therapy in long-term survival of patients with AIDS-related pulmonary aspergillosis. *Eur J Clin Microbiol Infect Dis* 2000;19:688–93.
- [235] Mylonakis E, Paliou M, Sax PE, Skolnik PR, Baron MJ, Rich JD. Central nervous system aspergillosis in patients with human immunodeficiency virus infection. Report of 6 cases and review. *Medicine (Balt)* 2000;79:269–80.
- [236] Lin SJ, Schranz J, Teutsch SM. Aspergillosis case-fatality rate: systematic review of the literature. *Clin Infect Dis* 2001;32:358–66.
- [237] Gastaca M, Aguero F, Rimola A, Montejo M, Miralles P, Lozano R, et al. Liver retransplantation in HIV-infected patients: a prospective cohort study. *Am J Transpl* 2012;12:2465–76.
- [238] Moreno A, Cervera C, Fortun J, Blanes M, Montejo E, Abradelo M, et al. Epidemiology and outcome of infections in human immunodeficiency virus/hepatitis C virus-coinfected liver transplant recipients: a FIPSE/GESIDA prospective cohort study. *Liver Transpl* 2012;18:70–81.
- [239] Woitas RP, Rockstroh JK, Theisen A, Leutner C, Sauerbruch T, Spengler U. Changing role of invasive aspergillosis in aids—a case–control study. *J Infect* 1998;37:116–22.
- [240] Lortholary O, Meyohas MC, Dupont B, Cadranet J, Salmon-Ceron D, Peyramond D, et al. Invasive aspergillosis in patients with acquired immunodeficiency syndrome: report of 33 cases. French cooperative study group on aspergillosis in AIDS. *Am J Med* 1993;95:177–87.
- [241] Denning DW, Follansbee SE, Scolaro M, Norris S, Edelstein H, Stevens DA. Pulmonary aspergillosis in the acquired immunodeficiency syndrome. *N Engl J Med* 1991;324:654–62.
- [242] Antinori S, Nebuloni M, Magni C, Fasan M, Adorni F, Viola A, et al. Trends in the postmortem diagnosis of opportunistic invasive fungal infections in patients with AIDS: a retrospective study of 1,630 autopsies performed between 1984 and 2002. *Am J Clin Pathol* 2009;132:221–7.
- [243] Chen J, Yang Q, Huang J, Li L. Clinical findings in 19 cases of invasive pulmonary aspergillosis with liver cirrhosis. *Multidiscip Resp Med* 2014;9:1.
- [244] Jeurissen S, Vogelaers D, Sermijn E, Van Dycke K, Geerts A, Van Vlierberghe H, et al. Invasive aspergillosis in patients with cirrhosis, a case report and review of the last 10 years. *Acta Clin Belg* 2013;68:368–75.
- [245] Vandewoude K, Blot S, Benoit D, Dupuydt P, Vogelaers D, Colardyn F. Invasive aspergillosis in critically ill patients: analysis of risk factors for acquisition and mortality. *Acta Clin Belg* 2004;59:251–7.
- [246] Cheruvattath R, Balan V. Infections in patients with end-stage liver disease. *J Clin Gastroenterol* 2007;41:403–11.
- [247] Falcone M, Massetti AP, Russo A, Vullo V, Venditti M. Invasive aspergillosis in patients with liver disease. *Med Mycol* 2011;49:406–13.
- [248] Russo A, Giuliano S, Vena A, Lucidi C, Falcone M, Raponi G, et al. Predictors of mortality in non-neutropenic patients with invasive pulmonary aspergillosis: does galactomannan have a role? *Diagn Microbiol Infect Dis* 2014;80:83–6.
- [249] Delsuc C, Cottreau A, Frealle E, Bienvenu AL, Dessein R, Jarraud S, et al. Putative invasive pulmonary aspergillosis in critically ill patients with chronic obstructive pulmonary disease: a matched cohort study. *Crit Care* 2015;19:421.
- [250] Tortorano AM, Dho G, Prgitano A, Breda G, Grancini A, Emmi V, et al. Invasive fungal infections in the intensive care unit: a multicentre, prospective, observational study in Italy (2006–2008). *Mycoses* 2012;55:73–9.
- [251] Jensen J, Guinea J, Torres-Narbona M, Munoz P, Pelaez T, Bouza E. Post-surgical invasive aspergillosis: an uncommon and under-appreciated entity. *J Infect* 2010;60:162–7.
- [252] Vehreschild JJ, Brockelmann PJ, Bangard C, Verheyen J, Vehreschild MJ, Michels G, et al. Pandemic 2009 influenza A(H1N1) virus infection coinciding with invasive pulmonary aspergillosis in neutropenic patients. *Epidemiol Infect* 2012;140:1848–52.
- [253] Garnacho-Montero J, Amaya-Villar R, Ortiz-Leyba C, Leon C, Alvarez-Lerma F, Nolla-Salas J, et al. Isolation of *Aspergillus* spp. from the respiratory tract in critically ill patients: risk factors, clinical presentation and outcome. *Crit Care* 2005;9:R1919.
- [254] Koulenti D, Garnacho-Montero J, Blot S. Approach to invasive pulmonary aspergillosis in critically ill patients. *Curr Opin Infect Dis* 2014;27:174–83.
- [255] Bassetti M, Righi E, De Pascale G, De Gaudio R, Giarratano A, Mazzei T, et al. How to manage aspergillosis in non-neutropenic intensive care unit patients. *Crit Care* 2014;18:458.
- [256] Dimopoulos G, Frantzeskaki F, Poulakou G, Armaganidis A. Invasive aspergillosis in the intensive care unit. *Ann N Y Acad Sci* 2012;1272:31–9.
- [257] Guinea J, Torres-Narbona M, Gijon P, Munoz P, Pozo F, Pelaez T, et al. Pulmonary aspergillosis in patients with chronic obstructive pulmonary disease: incidence, risk factors, and outcome. *Clin Microbiol Infect* 2010;16:870–7.
- [258] Tutar N, Metan G, Koc AN, Yilmaz I, Bozkurt I, Simsek ZO, et al. Invasive pulmonary aspergillosis in patients with chronic obstructive pulmonary disease. *Multidiscip Respir Med* 2013;8:59.
- [259] Giannella M, Munoz P, Guinea J, Escibano P, Rodriguez-Creixems M, Bouza E. Growth of *Aspergillus* in blood cultures: proof of invasive aspergillosis in patients with chronic obstructive pulmonary disease? *Mycoses* 2013;56:488–90.
- [260] Eworo A, Munoz P, Yanez JF, Palomo J, Guembe P, Roda J, et al. Cardiac invasive aspergillosis in a heart transplant recipient. *Rev Iberoam Micol* 2011;28:134–8.
- [261] El-Sayed Ahmed MM, Almanfi A, Aftab M, Singh SK, Mallidi HR, Frazier OH. *Aspergillus* mediastinitis after orthotopic heart transplantation: a case report. *Tex Heart Inst J* 2015;42:468–70.
- [262] Wiltberger C, Schmelzle M, Schubert S, Lubbert C, Brandmaier P, Berg T, et al. Invasive cardiac aspergillosis after orthotopic liver transplantation. *Z Gastroenterol* 2014;52:813–7.
- [263] Spapen H, Spapen J, Taccone FS, Meersseman W, Rello J, Dimopoulos G, et al. Cerebral aspergillosis in adult critically ill patients: a descriptive report of 10 patients from the ASPICU cohort. *Int J Antimicrob Agents* 2014;43:165–9.
- [264] Sole A, Ussetti P. Mold infections in lung transplants. *Rev Iberoam Micol* 2014;31:229–36.
- [265] Fortun J, Meije Y, Fresco G, Moreno S. Aspergillosis. Clinical forms and treatment. *Enferm Infecc Microbiol Clin* 2012;30:201–8.
- [266] Singh N, Sun HY. Iron overload and unique susceptibility of liver transplant recipients to disseminated disease due to opportunistic pathogens. *Liver Transpl* 2008;14:1249–55.
- [267] Shields RK, Nguyen MH, Shullo MA, Silveira FP, Kwak EJ, Abdel Massih RC, et al. Invasive aspergillosis among heart transplant recipients is rare but causes rapid death due to septic shock and multiple organ dysfunction syndrome. *Scand J Infect Dis* 2012;44:982–6.
- [268] Perfect JR, Cox GM, Lee JY, Kauffman CA, de Repentigny L, Chapman SW, et al. The impact of culture isolation of *Aspergillus* species: a hospital-based survey of aspergillosis. *Clin Infect Dis* 2001;33:1824–33.
- [269] Horvath JA, Dummer S. The use of respiratory-tract cultures in the diagnosis of invasive pulmonary aspergillosis. *Am J Med* 1996;100:171–8.
- [270] Escibano P, Marcos-Zambrano LJ, Pelaez T, Munoz P, Padilla B, Bouza E, et al. Sputum and bronchial secretion samples are equally useful as bronchoalveolar lavage samples for the diagnosis of invasive pulmonary aspergillosis in selected patients. *Med Mycol* 2015;53:235–40.
- [271] Munoz P, Alcalá L, Sanchez Conde M, Palomo J, Yanez J, Pelaez T, et al. The isolation of *Aspergillus fumigatus* from respiratory tract specimens in heart transplant recipients is highly predictive of invasive aspergillosis. *Transplantation* 2003;75:326–9.
- [272] Barton RC, Hobson RP, McLoughlin H, Morris A, Datta B. Assessment of the significance of respiratory culture of aspergillus in the non-neutropenic patient. A critique of published diagnostic criteria. *Eur J Clin Microbiol Infect Dis* 2013;32:923–8.
- [273] Zaspel U, Denning DW, Lemke AJ, Greene R, Schurmann D, Maschmeyer G, et al. Diagnosis of IPA in HIV: the role of the chest X-ray and radiologist. *Eur Radiol* 2004;14:2030–7.
- [274] Munoz P, Vena A, Ceron I, Valerio M, Palomo J, Guinea J, et al. Invasive pulmonary aspergillosis in heart transplant recipients: two radiologic patterns with a different prognosis. *J Heart Lung Transpl* 2014;33:1034–40.
- [275] Blot SI, Taccone FS, Van den Abeele AM, Bulpa P, Meersseman W, Brusselsaers N, et al. A clinical algorithm to diagnose invasive pulmonary aspergillosis in critically ill patients. *Am J Respir Crit Care Med* 2012;186:56–64.
- [276] Bulpa P, Dive A. Diagnosis of invasive bronchial-pulmonary aspergillosis in patients with chronic obstructive respiratory diseases. *Crit Care* 2011;15:420. author reply 420.
- [277] Singh N, Winston DJ, Limaye AP, Pelletier S, Safdar N, Morris MI, et al. Performance characteristics of galactomannan and β -d-glucan in high-risk liver transplant recipients. *Transplantation* 2015;99:2543–50.

- [278] Guinea J, Padilla C, Escribano P, Munoz P, Padilla B, Gijon P, et al. Evaluation of mycassay *Aspergillus* for diagnosis of invasive pulmonary aspergillosis in patients without hematological cancer. *PLoS One* 2013;8, e61545.
- [279] Zarrinfar H, Makimura K, Satoh K, Khodadadi H, Mirhendi H. Incidence of pulmonary aspergillosis and correlation of conventional diagnostic methods with nested PCR and real-time PCR assay using BAL fluid in intensive care unit patients. *J Clin Lab Anal* 2013;27:181–5.
- [280] Chong GL, van de Sande WW, Dingemans GJ, Gaajetaan GR, Vonk AG, Hayette MP, et al. Validation of a new *Aspergillus* real-time PCR assay for direct detection of *Aspergillus* and azole resistance of *Aspergillus fumigatus* on bronchoalveolar lavage fluid. *J Clin Microbiol* 2015;53:868–74.
- [281] Fortun J, Martin-Davila P, Gomez Garcia de la Pedrosa E, Silva JT, Garcia-Rodriguez J, Benito D, et al. Galactomannan in bronchoalveolar lavage fluid for diagnosis of invasive aspergillosis in non-hematological patients. *J Infect* 2016;72:738–44.
- [282] Fortun J, Martin-Davila P, Alvarez ME, Norman F, Sanchez-Sousa A, Gajate L, et al. False-positive results of *Aspergillus* galactomannan antigenemia in liver transplant recipients. *Transplantation* 2009;87:256–60.
- [283] Cai X, Ni W, Wei C, Cui J. Diagnostic value of the serum galactomannan and (1, 3)- β -D-glucan assays for invasive pulmonary aspergillosis in non-neutropenic patients. *Intern Med* 2014;53:2433–7.
- [284] Eigl S, Prattes J, Lackner M, Willinger B, Spiess B, Reinwald M, et al. Multi-center evaluation of a lateral-flow device test for diagnosing invasive pulmonary aspergillosis in ICU patients. *Crit Care* 2015;19:178.
- [285] Prattes J, Flick H, Pruller F, Koidl C, Raggam RB, Palfner M, et al. Novel tests for diagnosis of invasive aspergillosis in patients with underlying respiratory diseases. *Am J Respir Crit Care Med* 2014;190:922–9.
- [286] Lopez-Medrano F, Fernandez-Ruiz M, Silva JT, Carver PL, van Delden C, Merino E, et al. Clinical presentation and determinants of mortality of invasive pulmonary aspergillosis in kidney transplant recipients: a multinational cohort study. *Am J Transpl* 2016;16(11):3220–34.
- [287] Cherian T, Giakoustidis A, Yokoyama S, Heneghan M, O'Grady J, Rella M, et al. Treatment of refractory cerebral aspergillosis in a liver transplant recipient with voriconazole: case report and review of the literature. *Exp Clin Transpl* 2012;10:482–6.
- [288] Patel DA, Gao X, Stephens JM, Forshag MS, Tarallo M. US hospital database analysis of invasive aspergillosis in the chronic obstructive pulmonary disease non-traditional host. *J Med Econ* 2011;14:227–37.
- [289] Singh N, Limaye AP, Forrest G, Safdar N, Munoz P, Pursell K, et al. Combination of voriconazole and caspofungin as primary therapy for invasive aspergillosis in solid organ transplant recipients: a prospective, multicenter, observational study. *Transplantation* 2006;81:320–6.
- [290] Luong ML, Hosseini-Moghaddam SM, Singer LG, Chaparro C, Azad S, Lazar N, et al. Risk factors for voriconazole hepatotoxicity at 12 weeks in lung transplant recipients. *Am J Transpl* 2012;12:1929–35.
- [291] Shoham S, Ostrand D, Marr K. Posaconazole liquid suspension in solid organ transplant recipients previously treated with voriconazole. *Transpl Infect Dis* 2015;17:493–6.
- [292] Hoenigl M, Duettmann W, Raggam RB, Seeber K, Troppan K, Fruhwald S, et al. Potential factors for inadequate voriconazole plasma concentrations in intensive care unit patients and patients with hematological malignancies. *Antimicrob Agents Chemother* 2013;57:3262–7.
- [293] Kim SH, Kwon JC, Park C, Han S, Yim DS, Choi JK, et al. Therapeutic drug monitoring and safety of intravenous voriconazole formulated with sulfo-butylether β -cyclodextrin in hematological patients with renal impairment. *Mycoses* 2016;59(10):644–51.
- [294] Guinea J, Escribano P, Marcos-Zambrano LJ, Pelaez T, Kestler M, Munoz P, et al. Therapeutic drug monitoring of voriconazole helps to decrease the percentage of patients with off-target trough serum levels. *Med Mycol* 2016;54:353–60.
- [295] Vanstraelen K, Wauters J, Vercammen I, de Loo H, Maertens J, Lagrou K, et al. Impact of hypoalbuminemia on voriconazole pharmacokinetics in critically ill adult patients. *Antimicrob Agents Chemother* 2014;58:6782–9.
- [296] Shalhoub S, Luong ML, Howard SJ, Richardson S, Singer LG, Chaparro C, et al. Rate of cyp51a mutation in *Aspergillus fumigatus* among lung transplant recipients with targeted prophylaxis. *J Antimicrob Chemother* 2015;70:1064–7.
- [297] Escribano P, Pelaez T, Munoz P, Bouza E, Guinea J. Is azole resistance in *Aspergillus fumigatus* a problem in Spain? *Antimicrob Agents Chemother* 2013;57:2815–20.
- [298] Fuhren J, Voskuil WS, Boel CH, Haas PJ, Hagen F, Meis JF, et al. High prevalence of azole resistance in *Aspergillus fumigatus* isolates from high-risk patients. *J Antimicrob Chemother* 2015;70:2894–8.
- [299] Egli A, Fuller J, Humar A, Lien D, Weinkauff J, Nador R, et al. Emergence of *Aspergillus calidoustus* infection in the era of posttransplantation azole prophylaxis. *Transplantation* 2012;94:403–10.
- [300] Kuipers S, Bruggemann RJ, de Sevaux RG, Heesakkers JP, Melchers WJ, Mouton JW, et al. Failure of posaconazole therapy in a renal transplant patient with invasive aspergillosis due to *Aspergillus fumigatus* with attenuated susceptibility to posaconazole. *Antimicrob Agents Chemother* 2011;55:3564–6.
- [301] Singh N, Suarez JF, Avery R, Lass-Flörl C, Geltner C, Pasqualotto AC, et al. Immune reconstitution syndrome-like entity in lung transplant recipients with invasive aspergillosis. *Transpl Immunol* 2013;29:109–13.
- [302] Schaeferman JM. Is universal antifungal prophylaxis mandatory in lung transplant patients? *Curr Opin Infect Dis* 2013;26:317–25.
- [303] Tofte N, Jensen C, Tvede M, Andersen CB, Carlsen J, Iversen M. Use of prophylactic voriconazole for three months after lung transplantation does not reduce infection with *Aspergillus*: a retrospective study of 147 patients. *Scand J Infect Dis* 2012;44:835–41.
- [304] Bhaskaran A, Mumtaz K, Husain S. Anti-aspergillus prophylaxis in lung transplantation: a systematic review and meta-analysis. *Curr Infect Dis Rep* 2013;15:514–25.
- [305] Koo S, Kubiak DW, Issa NC, Dietzek A, Boukedes S, Camp PC, et al. A targeted peritransplant antifungal strategy for the prevention of invasive fungal disease after lung transplantation: a sequential cohort analysis. *Transplantation* 2012;94:281–6.
- [306] Munoz P, Rojas L, Cervera C, Garrido G, Farinas MC, Valerio M, et al. Poor compliance with antifungal drug use guidelines by transplant physicians: a framework for educational guidelines and an international consensus on patient safety. *Clin Transpl* 2012;26:87–96.
- [307] He SY, Makhzoumi ZH, Singer JP, Chin-Hong PV, Arron ST. Practice variation in aspergillus prophylaxis and treatment among lung transplant centers: a national survey. *Transpl Infect Dis* 2015;17:14–20.
- [308] Saliba F, Pascher A, Cointault O, Laterre PF, Cervera C, De Waele JJ, et al. Randomized trial of micafungin for the prevention of invasive fungal infection in high-risk liver transplant recipients. *Clin Infect Dis* 2015;60:997–1006.
- [309] Peghin M, Monforte V, Martin-Gomez MT, Ruiz-Camps I, Berastegui C, Saez B, et al. 10 years of prophylaxis with nebulized liposomal amphotericin B and the changing epidemiology of *Aspergillus* spp. infection in lung transplantation. *Transpl Int* 2016;29:51–62.
- [310] Patel TS, Eschenauer GA, Stuckey LJ, Carver PL. Antifungal prophylaxis in lung transplant recipients. *Transplantation* 2016;100(9):1815–26.
- [311] Fortun J, Muriel A, Martin-Davila P, Montejó M, Len O, Torre-Cisneros J, et al. Caspofungin versus fluconazole as prophylaxis of invasive fungal infection in high-risk liver transplantation recipients: a propensity score analysis. *Liver Transpl* 2016;22:427–35.
- [312] Kato K, Nagao M, Nakano S, Yunoki T, Hotta G, Yamamoto M, et al. Itracozazole prophylaxis for invasive aspergillus infection in lung transplantation. *Transpl Infect Dis* 2014;16:340–3.
- [313] Balogh J, Gordon Burroughs S, Boktour M, Patel S, Saharia A, Ochoa RA, et al. Efficacy and cost-effectiveness of voriconazole prophylaxis for prevention of invasive aspergillosis in high-risk liver transplant recipients. *Liver Transpl* 2016;22:163–70.
- [314] Aguado JM, Varo E, Usetti P, Pozo JC, Moreno A, Catalan M, et al. Safety of anidulafungin in solid organ transplant recipients. *Liver Transpl* 2012;18:680–5.
- [315] Husain S, Zaldonis D, Kusne S, Kwak EJ, Paterson DL, McCurry KR. Variation in antifungal prophylaxis strategies in lung transplantation. *Transpl Infect Dis* 2006;8:213–8.
- [316] Taccone A, Occhi M, Garaventa A, Manfredini L, Viscoli C. CT of invasive pulmonary aspergillosis in children with cancer. *Pediatr Radiol* 1993;23:177–80.
- [317] Archibald S, Park J, Geyer JR, Hawkins DS. Computed tomography in the evaluation of febrile neutropenic pediatric oncology patients. *Pediatr Infect Dis J* 2001;20:5–10.
- [318] Burgos A, Zaoutis TE, Dvorak CC, Hoffman JA, Knapp KM, Nania JJ, et al. Pediatric invasive aspergillosis: a multicenter retrospective analysis of 139 contemporary cases. *Pediatrics* 2008;121:e1286–94.
- [319] Pfeiffer CD, Fine JP, Safdar N. Diagnosis of invasive aspergillosis using a galactomannan assay: a meta-analysis. *Clin Infect Dis* 2006;42:1417–27.
- [320] Hovi L, Saxen H, Saarinen-Pihkala UM, Vettentranta K, Meri T, Richardson M. Prevention and monitoring of invasive fungal infections in pediatric patients with cancer and hematologic disorders. *Pediatr Blood Cancer* 2007;48:28–34.
- [321] Steinbach WJ, Addison RM, McLaughlin L, Gerrald Q, Martin PL, Driscoll T, et al. Prospective aspergillus galactomannan antigen testing in pediatric hematopoietic stem cell transplant recipients. *Pediatr Infect Dis J* 2007;26:558–64.
- [322] Hayden R, Pounds S, Knapp K, Petraitiene R, Schaufele RL, Sein T, et al. Galactomannan antigenemia in pediatric oncology patients with invasive aspergillosis. *Pediatr Infect Dis J* 2008;27:815–9.
- [323] Castagnola E, Furfaro E, Caviglia I, Licciardello M, Faraci M, Fioredda F, et al. Performance of the galactomannan antigen detection test in the diagnosis of invasive aspergillosis in children with cancer or undergoing haemopoietic stem cell transplantation. *Clin Microbiol Infect* 2010;16:1197–203.
- [324] Fisher BT, Zaoutis TE, Park JR, Bleakley M, Englund JA, Kane C, et al. Galactomannan antigen testing for diagnosis of invasive aspergillosis in pediatric hematology patients. *J Pediatr Infect Dis Soc* 2012;1:103–11.
- [325] Choi SH, Kang ES, Eo H, Yoo SY, Kim JH, Yoo KH, et al. Aspergillus galactomannan antigen assay and invasive aspergillosis in pediatric cancer patients and hematopoietic stem cell transplant recipients. *Pediatr Blood Cancer* 2013;60:316–22.
- [326] Jha AK, Bansal D, Chakrabarti A, Shivaprakash MR, Trehan A, Marwaha RK. Serum galactomannan assay for the diagnosis of invasive aspergillosis in children with hematological malignancies. *Mycoses* 2013;56:442–8.
- [327] Dinand V, Anjan M, Oberoi JK, Khanna S, Yadav SP, Watal C, et al. Threshold of galactomannan antigenemia positivity for early diagnosis of invasive

- aspergillosis in neutropenic children. *J Microbiol Immunol Infect* 2016;49:66–73.
- [328] Smith PB, Benjamin Jr DK, Alexander BD, Johnson MD, Finkelman MA, Steinbach WJ. Quantification of 1,3- β -D-glucan levels in children: preliminary data for diagnostic use of the β -glucan assay in a pediatric setting. *Clin Vaccine Immunol* 2007;14:924–5.
- [329] Zhao L, Tang JY, Wang Y, Zhou YF, Chen J, Li BR, et al. Value of plasma β -glucan in early diagnosis of invasive fungal infection in children. *Zhongguo Dang Dai Er Ke Za Zhi* 2009;11:905–8.
- [330] Mularoni A, Furfaro E, Faraci M, Franceschi A, Mezzano P, Bandettini R, et al. High levels of β -D-glucan in immunocompromised children with proven invasive fungal disease. *Clin Vaccine Immunol* 2010;17:882–3.
- [331] Badiie P, Alborzi A, Karimi M, Pourabbas B, Haddadi P, Mardaneh J, et al. Diagnostic potential of nested PCR, galactomannan EIA, and β -D-glucan for invasive aspergillosis in pediatric patients. *J Infect Dev Ctries* 2012;6:352–7.
- [332] Koltze A, Rath P, Schoning S, Steinmann J, Wichelhaus TA, Bader P, et al. β -D-glucan screening for detection of invasive fungal disease in children undergoing allogeneic hematopoietic stem cell transplantation. *J Clin Microbiol* 2015;53:2605–10.
- [333] Denning DW, Ribaud P, Milpied N, Caillot D, Herbrecht R, Thiel E, et al. Efficacy and safety of voriconazole in the treatment of acute invasive aspergillosis. *Clin Infect Dis* 2002;34:563–71.
- [334] Walsh TJ, Lutsar I, Driscoll T, Dupont B, Roden M, Ghahramani P, et al. Voriconazole in the treatment of aspergillosis, scedosporiosis and other invasive fungal infections in children. *Pediatr Infect Dis J* 2002;21:240–8.
- [335] Maertens J, Raad I, Petrikos G, Boogaerts M, Selleslag D, Petersen FB, et al. Efficacy and safety of caspofungin for treatment of invasive aspergillosis in patients refractory to or intolerant of conventional antifungal therapy. *Clin Infect Dis* 2004;39:1563–71.
- [336] Raad II, Hanna HA, Boktour M, Jiang Y, Torres HA, Afif C, et al. Novel antifungal agents as salvage therapy for invasive aspergillosis in patients with hematologic malignancies: posaconazole compared with high-dose lipid formulations of amphotericin B alone or in combination with caspofungin. *Leukemia* 2008;22:496–503.
- [337] Cornely OA, Maertens J, Bresnik M, Ullmann AJ, Ebrahimi R, Herbrecht R. Treatment outcome of invasive mould disease after sequential exposure to azoles and liposomal amphotericin B. *J Antimicrob Chemother* 2010;65:114–7.
- [338] Winston DJ, Bartoni K, Territo MC, Schiller GJ. Efficacy, safety, and breakthrough infections associated with standard long-term posaconazole antifungal prophylaxis in allogeneic stem cell transplantation recipients. *Biol Blood Marrow Transpl* 2011;17:507–15.
- [339] De la Serna J, Jarque I, Lopez-Jimenez J, Fernandez-Navarro JM, Gomez V, Jurado M, et al. Treatment of invasive fungal infections in high risk hematological patients. The outcome with liposomal amphotericin B is not negatively affected by prior administration of mold-active azoles. *Rev Esp Quimioter* 2013;26:64–9.
- [340] Auberger J, Lass-Flörl C, Aigner M, Clausen J, Gastl G, Nachbaur D. Invasive fungal breakthrough infections, fungal colonization and emergence of resistant strains in high-risk patients receiving antifungal prophylaxis with posaconazole: real-life data from a single-centre institutional retrospective observational study. *J Antimicrob Chemother* 2012;67:2268–73.
- [341] Lehnbecher T, Kalkum M, Champer J, Tramsen L, Schmidt S, Klingebiel T. Immunotherapy in invasive fungal infection—focus on invasive aspergillosis. *Curr Pharmaceut Des* 2013;19:3689–712.
- [342] Prentice HG, Hann IM, Herbrecht R, Aoun M, Kvaloy S, Catovsky D, et al. A randomized comparison of liposomal versus conventional amphotericin B for the treatment of pyrexia of unknown origin in neutropenic patients. *Br J Haematol* 1997;98:711–8.
- [343] Maertens JA, Madero L, Reilly AF, Lehnbecher T, Groll AH, Jafri HS, et al. A randomized, double-blind, multicenter study of caspofungin versus liposomal amphotericin B for empiric antifungal therapy in pediatric patients with persistent fever and neutropenia. *Pediatr Infect Dis J* 2010;29:415–20.
- [344] Caselli D, Paolicchi O. Empiric antibiotic therapy in a child with cancer and suspected septicemia. *Pediatr Rep* 2012;4. e2.
- [345] Tan BH, Low JG, Chlebicka NL, Kurup A, Cheah FK, Lin RT, et al. Galactomannan-guided preemptive vs. empirical antifungals in the persistently febrile neutropenic patient: a prospective randomized study. *Int J Infect Dis* 2011;15:e350–6.
- [346] Castagnola E, Bagnasco F, Amoroso L, Caviglia I, Caruso S, Faraci M, et al. Role of management strategies in reducing mortality from invasive fungal disease in children with cancer or receiving hemopoietic stem cell transplant: a single center 30-year experience. *Pediatr Infect Dis J* 2014;33:233–7.
- [349] Segal BH, Herbrecht R, Stevens DA, Ostrosky-Zeichner L, Sobel J, Viscoli C, et al. Defining responses to therapy and study outcomes in clinical trials of invasive fungal diseases: Mycoses Study Group and European Organization for Research and Treatment of Cancer Consensus Criteria. *Clin Infect Dis* 2008;47:674–83.
- [350] Vehreschild JJ, Heussel CP, Groll AH, Vehreschild MJ, Silling G, Wurthwein G, et al. Serial assessment of pulmonary lesion volume by computed tomography allows survival prediction in invasive pulmonary aspergillosis. *Eur Radiol* 2017;27(8):3275–82.
- [351] Nucci M, Perfect JR. When primary antifungal therapy fails. *Clin Infect Dis* 2008;46:1426–33.
- [352] Bennett JE. Salvage therapy for aspergillosis. *Clin Infect Dis* 2005;41(Suppl. 6):S387–8.
- [353] Bergeron A, Porcher R, Menotti J, Poirot JL, Chagnon K, Vekhoff A, et al. Prospective evaluation of clinical and biological markers to predict the outcome of invasive pulmonary aspergillosis in hematological patients. *J Clin Microbiol* 2012;50:823–30.
- [354] Maertens J, Buve K, Theunissen K, Meersseman W, Verbeken E, Verhoef G, et al. Galactomannan serves as a surrogate endpoint for outcome of pulmonary invasive aspergillosis in neutropenic hematology patients. *Cancer* 2009;115:355–62.
- [355] Boutboul F, Alberti C, Leblanc T, Sulahian A, Gluckman E, Derouin F, et al. Invasive aspergillosis in allogeneic stem cell transplant recipients: increasing antigenemia is associated with progressive disease. *Clin Infect Dis* 2002;34:939–43.
- [356] Miceli MH, Maertens J, Buve K, Graziutti M, Woods G, Rahman M, et al. Immune reconstitution inflammatory syndrome in cancer patients with pulmonary aspergillosis recovering from neutropenia: proof of principle, description, and clinical and research implications. *Cancer* 2007;110:112–20.
- [357] Almyroudis NG, Kontoyiannis DP, Sepkowitz KA, DePauw BE, Walsh TJ, Segal BH. Issues related to the design and interpretation of clinical trials of salvage therapy for invasive mold infection. *Clin Infect Dis* 2006;43:1449–55.
- [358] Smith NL, Denning DW. Underlying conditions in chronic pulmonary aspergillosis including simple aspergilloma. *Eur Respir J* 2011;37:865–72.
- [359] Salzer HJ, Cornely OA. Awareness of predictors of mortality may help improve outcome in chronic pulmonary aspergillosis. *Eur Respir J* 2017;49.
- [360] Muldoon EG, Sharman A, Page I, Bishop P, Denning DW. Aspergillus nodules; another presentation of chronic pulmonary aspergillosis. *BMC Pulm Med* 2016;16:123.
- [361] Salzer HJ, Heyckendorf J, Kalsdorf B, Rolling T, Lange C. Characterization of patients with chronic pulmonary aspergillosis according to the new ESCMID/ERS/ECMM and IDSA guidelines. *Mycoses* 2017;60:136–42.
- [362] Dumollard C, Bailly S, Perriot S, Brenier-Pinchart MP, Saint-Raymond C, Camara B, et al. Prospective evaluation of a new aspergillus IgG enzyme immunoassay kit for diagnosis of chronic and allergic pulmonary aspergillosis. *J Clin Microbiol* 2016;54:1236–42.
- [363] Farid S, Mohamed S, Devbhandari M, Kneale M, Richardson M, Soon SY, et al. Results of surgery for chronic pulmonary aspergillosis, optimal antifungal therapy and proposed high risk factors for recurrence—a national centre's experience. *J Cardiothorac Surg* 2013;8:180.
- [364] Cadranel J, Philippe B, Hennequin C, Bergeron A, Bergot E, Bourdin A, et al. Voriconazole for chronic pulmonary aspergillosis: a prospective multicenter trial. *Eur J Clin Microbiol Infect Dis* 2012;31:3231–9.
- [365] Al-Shair K, Atherton GT, Harris C, Ratcliffe L, Newton PJ, Denning DW. Long-term antifungal treatment improves health status in patients with chronic pulmonary aspergillosis: a longitudinal analysis. *Clin Infect Dis* 2013;57:828–35.
- [366] Pasmans HL, Loosveld OJ, Schouten HC, Thunnissen F, van Engelshoven JM. Invasive aspergillosis in immunocompromised patients: findings on plain film and (hr)CT. *Eur J Radiol* 1992;14:37–40.
- [367] Heussel CP, Kauczor HU, Heussel G, Mildnerberger P, Dueber C. Aneurysms complicating inflammatory diseases in immunocompromised hosts: value of contrast-enhanced CT. *Eur Radiol* 1997;7:316–9.
- [368] Didier M, Guedin P, Staub F, Catherinot E, Rivaud E, Scherrer A, et al. Pulmonary arterial mycotic pseudoaneurysms in a patient with invasive pulmonary aspergillosis. Successful occlusion by coils. *Am J Resp Crit Care Med* 2014;190:112–3.
- [369] Denning DW, Kibbler CC, Barnes RA, British Society for Medical M. British society for medical mycology proposed standards of care for patients with invasive fungal infections. *Lancet Infect Dis* 2003;3:230–40.
- [370] Vyzantiadis TA, Johnson EM, Kibbler CC. From the patient to the clinical mycology laboratory: how can we optimise microscopy and culture methods for mould identification? *J Clin Pathol* 2012;65:475–83.
- [371] Choi JK, Mauger J, McGowan KL. Immunohistochemical detection of *Aspergillus* species in pediatric tissue samples. *J Clin Pathol* 2004;121:18–25.
- [372] Kaufman L, Standard PG, Jalbert M, Kraft DE. Immunohistologic identification of *Aspergillus* spp. and other hyaline fungi by using polyclonal fluorescent antibodies. *J Clin Microbiol* 1997;35:2206–9.
- [373] Verweij PE, Smedts F, Poot T, Bult P, Hoogkamp-Korstanje JA, Meis JF. Immunoperoxidase staining for identification of *Aspergillus* species in routinely processed tissue sections. *J Clin Pathol* 1996;49:798–801.
- [374] Hayden RT, Isotalo PA, Parrett T, Wolk DM, Qian X, Roberts GD, et al. In situ hybridization for the differentiation of *Aspergillus*, *Fusarium*, and *Pseudallescheria* species in tissue section. *Diagn Mol Pathol* 2003;12:21–6.
- [375] Sundaram C, Umabala P, Laxmi V, Purohit AK, Prasad VS, Panigrahi M, et al. Pathology of fungal infections of the central nervous system: 17 years' experience from southern India. *Histopathology* 2006;49:396–405.
- [376] Chander J, Chakrabarti A, Sharma A, Saini JS, Panigrahi D. Evaluation of calcofluor staining in the diagnosis of fungal corneal ulcer. *Mycoses* 1993;36:243–5.
- [377] Baxter CG, Jones AM, Webb K, Denning DW. Homogenisation of cystic fibrosis sputum by sonication—an essential step for *Aspergillus* PCR. *J Microbiol Methods* 2011;85:75–81.

- [378] Cuenca-Estrella M, Bassetti M, Lass-Flörl C, Ręcil Z, Richardson M, Rogers TR. Detection and investigation of invasive mould disease. *J Antimicrob Chemother* 2011;66:i15–24.
- [379] Richardson M, Ellis M. Clinical and laboratory diagnosis. *Hosp Med* 2000;61: 610–4.
- [380] Alanio A, Beretti JL, Dauphin B, Mellado E, Quesne G, Lacroix C, et al. Matrix-assisted laser desorption ionization time-of-flight mass spectrometry for fast and accurate identification of clinically relevant *Aspergillus* species. *Clin Microbiol Infect* 2011;17:750–5.
- [381] Bille E, Dauphin B, Leto J, Bougnoux ME, Beretti JL, Lotz A, et al. Maldi-tof ms andromas strategy for the routine identification of bacteria, mycobacteria, yeasts, *Aspergillus* spp. and positive blood cultures. *Clin Microbiol Infect* 2012;18:1117–25.
- [382] De Carolis E, Vella A, Florio AR, Posteraro P, Perlin DS, Sanguinetti M, et al. Use of matrix-assisted laser desorption ionization-time of flight mass spectrometry for caspofungin susceptibility testing of *Candida* and *Aspergillus* species. *J Clin Microbiol* 2012;50:2479–83.
- [383] Lau AF, Drake SK, Calhoun LB, Henderson CM, Zelazny AM. Development of a clinically comprehensive database and a simple procedure for identification of molds from solid media by matrix-assisted laser desorption ionization-time of flight mass spectrometry. *J Clin Microbiol* 2013;51:828–34.
- [384] Balajee SA, Borman AM, Brandt ME, Cano J, Cuenca-Estrella M, Dannaoui E, et al. Sequence-based identification of *Aspergillus*, *Fusarium*, and *Mucorales* species in the clinical mycology laboratory: where are we and where should we go from here? *J Clin Microbiol* 2009;47:877–84.
- [385] Samson RA, Hong S, Peterson SW, Frisvad JC, Varga J. Polyphasic taxonomy of *Aspergillus* section *fumigati* and its teleomorph *Neosartorya*. *Stud Mycol* 2007;59:147–203.
- [386] Caramalho R, Gusmão L, Lackner M, Amorim A, Araujo R. Snapafu: a novel single nucleotide polymorphism multiplex assay for *Aspergillus fumigatus* direct detection, identification and genotyping in clinical specimens. *PLoS One* 2013;8, e75968.
- [387] Hurst SF, Kidd SE, Morrissey CO, Snelders E, Melchers WJ, Castelli MV, et al. Interlaboratory reproducibility of a single-locus sequence-based method for strain typing of *Aspergillus fumigatus*. *J Clin Microbiol* 2009;47:1562–4.
- [388] Guinea J, García de Viedma D, Peláez T, Escribano P, Munoz P, Meis JF, et al. Molecular epidemiology of *Aspergillus fumigatus*: an in-depth genotypic analysis of isolates involved in an outbreak of invasive aspergillosis. *J Clin Microbiol* 2011;49:3498–503.
- [389] Rougeron A, Giraud S, Razafimandimby B, Meis JF, Bouchara JP, Klaassen CH. Different colonization patterns of *Aspergillus terreus* in patients with cystic fibrosis. *Clin Microbiol Infect* 2014;20:327–33.
- [390] Maertens J, Van Eldere J, Verhaegen J, Verbeken E, Verschakelen J, Boogaerts M. Use of circulating galactomannan screening for early diagnosis of invasive aspergillosis in allogeneic stem cell transplant recipients. *J Infect Dis* 2002;186:1297–306.
- [391] Leeflang MM, Debets-Ossenkopp YJ, Visser CE, Scholten RJ, Hoofst L, Bijlmer HA, et al. Galactomannan detection for invasive aspergillosis in immunocompromised patients. *Cochrane Collab* 2008;4, CD007394.
- [392] Furfaro E, Mikulska M, Miletich F, Viscoli C. Galactomannan: testing the same sample twice? *Transpl Infect Dis* 2012;14:E38–9.
- [393] Morrissey CO, Chen SC, Sorrell TC, Milliken S, Bardy PG, Bradstock KF, et al. Galactomannan and PCR versus culture and histology for directing use of antifungal treatment for invasive aspergillosis in high-risk haematology patients: a randomised controlled trial. *Lancet Infect Dis* 2013;13:519–28.
- [394] Maertens J, Verhaegen J, Lagrou K, Van Eldere J, Boogaerts M. Screening for circulating galactomannan as a noninvasive diagnostic tool for invasive aspergillosis in prolonged neutropenic patients and stem cell transplantation recipients: a prospective validation. *Blood* 2001;97:1604–10.
- [395] Hoenigl M, Seeber K, Koidl C, Buzina W, Wilfler A, Duettmann W, et al. Sensitivity of galactomannan enzyme immunoassay for diagnosing breakthrough invasive aspergillosis under antifungal prophylaxis and empirical therapy. *Mycoses* 2013;56:471–6.
- [396] Marr KA, Laverdiere M, Gugel A, Leisenring W. Antifungal therapy decreases sensitivity of the *Aspergillus* galactomannan enzyme immunoassay. *Clin Infect Dis* 2005;40:1762–9.
- [397] Cordonnier C, Botterel F, Ben Amor R, Pautas C, Maury S, Kuentz M, et al. Correlation between galactomannan antigen levels in serum and neutrophil counts in haematological patients with invasive aspergillosis. *Clin Microbiol Infect* 2009;15:81–6.
- [398] Maertens J, Theunissen K, Verhoef G, Verschakelen J, Lagrou K, Verbeken E, et al. Galactomannan and computed tomography-based preemptive antifungal therapy in neutropenic patients at high risk for invasive fungal infection: a prospective feasibility study. *Clin Infect Dis* 2005;41:1242–50.
- [399] Guinea J, Jensen J, Peláez T, Gijón P, Alonso R, Rivera M, et al. Value of a single galactomannan determination (platelia) for the diagnosis of invasive aspergillosis in non-hematological patients with clinical isolation of *Aspergillus* spp. *Med Mycol* 2008;46:575–9.
- [400] Husain S, Kwak EJ, Obman A, Wagener MM, Kusne S, Stout JE, et al. Prospective assessment of platelia *Aspergillus* galactomannan antigen for the diagnosis of invasive aspergillosis in lung transplant recipients. *Am J Transpl* 2004;4:796–802.
- [401] Tabarsi P, Soraghi A, Marjani M, Zandian P, Baghaei P, Najafzadeh K, et al. Comparison of serum and bronchoalveolar lavage galactomannan in diagnosing invasive aspergillosis in solid-organ transplant recipients. *Exp Clin Transpl* 2012;10:278–81.
- [402] Guigue N, Menotti J, Ribaud P. False positive galactomannan test after ice-pop ingestion. *N Engl J Med* 2013;369:97–8.
- [403] Petraitiene R, Petraitis V, Witt 3rd JR, Durkin MM, Bacher JD, Wheat LJ, et al. Galactomannan antigenemia after infusion of gluconate-containing plasma-lyte. *J Clin Microbiol* 2011;49:4330–2.
- [404] Martin-Rabadan P, Gijon P, Alonso Fernandez R, Ballesteros M, Anguita J, Bouza E. False-positive aspergillus antigenemia due to blood product conditioning fluids. *Clin Infect Dis* 2012;5:e22–7.
- [405] Mikulska M, Furfaro E, Del Bono V, Raiola AM, Ratto S, Bacigalupo A, et al. Piperacillin/tazobactam (tazocintm) seems to be no longer responsible for false-positive results of the galactomannan assay. *J Antimicrob Chemother* 2012;67:1746–8.
- [406] Vergidis P, Walker RC, Kaul DR, Kauffman CA, Freifeld AG, Slagle DC, et al. False-positive *Aspergillus* galactomannan assay in solid organ transplant recipients with histoplasmosis. *Transpl Infect Dis* 2012;14:213–7.
- [407] Huang YT, Hung CC, Liao CH, Sun HY, Chang SC, Chen YC. Detection of circulating galactomannan in serum samples for diagnosis of *Penicillium marneffei* infection and cryptococcosis among patients infected with human immunodeficiency virus. *J Clin Microbiol* 2007;45:2858–62.
- [408] Nucci M, Carlesse F, Cappellano P, Varon AG, Seber A, Garnica M, et al. Earlier diagnosis of invasive fusariosis with *Aspergillus* serum galactomannan testing. *PLoS One* 2014;9, e87784.
- [409] King ST, Stover KR. Considering confounders of the galactomannan index: the role of piperacillin-tazobactam. *Clin Infect Dis* 2014;58:751–2.
- [410] Chai LY, Kullberg BJ, Johnson EM, Teerenstra S, Khin LW, Vonk AG, et al. Early serum galactomannan trend as a predictor of outcome of invasive aspergillosis. *J Clin Microbiol* 2012;50:2330–6.
- [411] Reinwald M, Spiess B, Heinz WJ, Vehreschild JJ, Lass-Flörl C, Kiehl M, et al. Diagnosing pulmonary aspergillosis in patients with hematological malignancies: a multicenter prospective evaluation of an *Aspergillus* PCR assay and a galactomannan elisa in bronchoalveolar lavage sample. *Eur J Haematol* 2012;89:120–7.
- [412] Heng SC, Morrissey O, Chen SC, Thursky K, Manser RL, Nation RL, et al. Utility of bronchoalveolar lavage fluid galactomannan alone or in combination with PCR for the diagnosis of invasive aspergillosis in adult hematology patients: a systematic review and meta-analysis. *Crit Rev Microbiol* 2015;41:124–34.
- [413] Zou M, Tang L, Zhao S, Zhao Z, Chen L, Chen P, et al. Systematic review and meta-analysis of detecting galactomannan in bronchoalveolar lavage fluid for diagnosing invasive aspergillosis. *PLoS One* 2012;7, e43347.
- [414] Fisher CE, Stevens AM, Leisenring W, Pergam SA, Boeckh M, Hohl TM. The serum galactomannan index predicts mortality in hematopoietic stem cell transplant recipients with invasive aspergillosis. *Clin Infect Dis* 2013;57: 1001–4.
- [415] Verweij PE, Brinkman K, Kremer HP, Kullberg BJ, Meis JF. *Aspergillus* meningitis: diagnosis by non-culture-based microbiological methods and management. *J Clin Microbiol* 1999;37:1186–9.
- [416] Viscoli C, Machetti M, Gazzola P, De Maria A, Paola D, Van Lint MT, et al. *Aspergillus* galactomannan antigen in the cerebrospinal fluid of bone marrow transplant recipients with probable cerebral aspergillosis. *J Clin Microbiol* 2002;40:1496–9.
- [417] Klont RR, Mennink-Kersten MA, Verweij PE. Utility of *Aspergillus* antigen detection in specimens other than serum specimens. *Clin Infect Dis* 2004;39: 1467–74.
- [418] Lu Y, Chen YQ, Guo YL, Qin SM, Wu C, Wang K. Diagnosis of invasive fungal disease using serum (1-3)- β -d-glucan: a bivariate meta-analysis. *Intern Med* 2011;50:2783–91.
- [419] Lamoth F, Cruciani M, Mengoli C, Castagnola E, Lortholary O, Richardson M, et al. β -glucan antigenemia assay for the diagnosis of invasive fungal infections in patients with hematological malignancies: a systematic review and meta-analysis of cohort studies from the third European Conference on Infections in Leukemia (ECIL-3). *Clin Infect Dis* 2012;54:633–43.
- [420] Senn L, Robinson JO, Schmidt S, Knaup M, Asahi N, Satomura S, et al. 1,3- β -d-glucan antigenemia for early diagnosis of invasive fungal infections in neutropenic patients with acute leukemia. *Clin Infect Dis* 2008;46:878–85.
- [421] Ellis M, Al-Ramadi B, Finkelman M, Hedstrom U, Kristensen J, Ali-Zadeh H, et al. Assessment of the clinical utility of serial β -d-glucan concentrations in patients with persistent neutropenic fever. *J Med Microbiol* 2008;57:287–95.
- [422] Kawazu M, Kanda Y, Nannya Y, Aoki K, Kurokawa M, Chiba S, et al. Prospective comparison of the diagnostic potential of real-time PCR, double-sandwich enzyme-linked immunosorbent assay for galactomannan, and a (1-3)- β -d-glucan test in weekly screening for invasive aspergillosis in patients with hematological disorders. *J Clin Microbiol* 2004;42:2733–41.
- [423] Odabasi Z, Mattiuzzi G, Estey E, Kantarjian H, Saeki F, Ridge RJ, et al. β -d-glucan as a diagnostic adjunct for invasive fungal infections: validation, cutoff development, and performance in patients with acute myelogenous leukemia and myelodysplastic syndrome. *Clin Infect Dis* 2004;39:199–205.
- [424] Ostrosky-Zeichner L, Alexander BD, Kett DH, Vazquez J, Pappas PG, Saeki F, et al. Multicenter clinical evaluation of the (1-3) β -d-glucan assay as an aid to diagnosis of fungal infections in humans. *Clin Infect Dis* 2005;41:654–9.
- [425] De Vlieger G, Lagrou K, Maertens J, Verbeken E, Meersseman W, Van Wijngaerden E. β -d-glucan detection as a diagnostic test for invasive aspergillosis in immunocompromised critically ill patients with symptoms of

- respiratory infection: an autopsy-based study. *J Clin Microbiol* 2011;49:3783–7.
- [426] Del Bono V, Delfino E, Furfaro E, Mikulska M, Nicco E, Bruzzi P, et al. Clinical performance of the (1,3)- β -d-glucan assay in early diagnosis of nosocomial *Candida* bloodstream infections. *Clin Vaccine Immunol* 2011;18:2113–7.
- [427] Acosta J, Catalan M, del Palacio-Pérez-Medel A, Montejo JC, De-La-Cruz-Bértolo J, Moraques MD, et al. Prospective study in critically ill non-neutropenic patients: diagnostic potential of (1,3)- β -d-glucan assay and circulating galactomannan for the diagnosis of invasive fungal disease. *Eur J Clin Microbiol Infect Dis* 2012;31:721–31.
- [428] Hoenigl M, Koidl C, Duettmann W, Seeber K, Wagner J, Buzina W, et al. Bronchoalveolar lavage lateral-flow device test for invasive pulmonary aspergillosis diagnosis in haematological malignancy and solid organ transplant patients. *J Infect* 2012;65:588–91.
- [429] Held J, Schmidt T, Thornton CR, Kotter E, Bertz H. Comparison of a novel *Aspergillus* lateral-flow device and the platelia α galactomannan assay for the diagnosis of invasive aspergillosis following haematopoietic stem cell transplantation. *Infection* 2013;41:1163–9.
- [430] Hoenigl M, Prattes J, Spiess B, Wagner J, Pruehler F, Raggam RB, et al. Performance of galactomannan, β -d-glucan, *Aspergillus* lateral-flow device, conventional culture, and PCR tests with bronchoalveolar lavage fluid for diagnosis of invasive pulmonary aspergillosis. *J Clin Microbiol* 2014;52:2039–45.
- [431] Einsele H, Quabeck K, Müller KD, Hebart H, Rothenhifer I, Löffler J, et al. Prediction of invasive pulmonary aspergillosis from colonisation of lower respiratory tract before marrow transplantation. *Lancet* 1998;352:1443.
- [432] Tang CM, Holden DW, Aufauvre-Brown A, Cohen J. The detection of *Aspergillus* spp. by the polymerase chain reaction and its evaluation in bronchoalveolar lavage fluid. *Am Rev Respir Dis* 1993;148:1313–7.
- [433] Verweij PE, Latge JP, Rijs AJ, Melchers WJ, De Pauw BE, Hoogkamp-Korstanje JA, et al. Comparison of antigen detection and PCR assay using bronchoalveolar lavage fluid for diagnosing invasive pulmonary aspergillosis in patients receiving treatment for hematological malignancies. *J Clin Microbiol* 1995;33:3150–3.
- [434] Bretagne S, Costa JM, Marmorat-Khuong A, Poron F, Cordonnier C, Vidaud M, et al. Detection of *Aspergillus* species DNA in bronchoalveolar lavage samples by competitive PCR. *J Clin Microbiol* 1995;33:1164–8.
- [435] Jones ME, Fox AJ, Barnes AJ, Oppenheim BA, Balagopal P, Morgenstern GR, et al. PCR-ELISA for the early diagnosis of invasive pulmonary aspergillosis infection in neutropenic patients. *J Clin Pathol* 1998;51:652–6.
- [436] Skladny H, Buchheidt D, Baust C, Krieg-Schneider F, Seifarth W, Leib-Misch C, et al. Specific detection of *Aspergillus* species in blood and bronchoalveolar lavage samples of immunocompromised patients by two-step PCR. *J Clin Microbiol* 1999;37:3865–71.
- [437] Buchheidt D, Baust C, Skladny H, Ritter J, Suedhoff T, Baldus M, et al. Detection of *Aspergillus* species in blood and bronchoalveolar lavage samples from immunocompromised patients by means of 2-step polymerase chain reaction: clinical results. *Clin Infect Dis* 2001;33:428–35.
- [438] Hayette MP, Vaira D, Susin F, Boland P, Christiaens G, Melin P, et al. Detection of aspergillus species DNA by PCR in bronchoalveolar lavage fluid. *J Clin Microbiol* 2001;39:2338–40.
- [439] Melchers WJ, Verweij PE, van den Hurk P, van Belkum A, De Pauw BE, Hoogkamp-Korstanje JA, et al. General primer-mediated PCR for detection of *Aspergillus* species. *J Clin Microbiol* 1994;32:1710–7.
- [440] Buchheidt D, Baust C, Skladny H, Baldus M, Bräuninger S, Hehlmann R. Clinical evaluation of a polymerase chain reaction assay to detect *Aspergillus* species in bronchoalveolar lavage samples of neutropenic patients. *Br J Haematol* 2002;116:803–11.
- [441] Raad I, Hanna H, Huaranga A, Sumoza D, Hachem R, Albitar M. Diagnosis of invasive pulmonary aspergillosis using polymerase chain reaction-based detection of *Aspergillus* in BAL. *Chest* 2002;121:1171–6.
- [442] Spiess B, Buchheidt D, Baust C, Skladny H, Seifarth W, Zeifelder U, et al. Development of a lightcycler PCR assay for detection and quantification of *Aspergillus fumigatus* DNA in clinical samples from neutropenic patients. *J Clin Microbiol* 2003;41:1811–8.
- [443] Meltiadis J, Melchers WJ, Meis JF, van den Hurk P, Jannes G, Verweij PE. Evaluation of a polymerase chain reaction reverse hybridization line probe assay for the detection and identification of medically important fungi in bronchoalveolar lavage fluids. *Med Mycol* 2003;41:65–74.
- [444] Sanguinetti M, Posteraro B, Pagano L, Pagliari G, Fianchi L, Mele L, et al. Comparison of real-time PCR, conventional PCR, and galactomannan antigen detection by enzyme-linked immunosorbent assay using bronchoalveolar lavage fluid samples from hematology patients for diagnosis of invasive pulmonary aspergillosis. *J Clin Microbiol* 2003;41:3922–5.
- [445] Rantakokko-Jalava K, Laaksonen S, Issakainen J, Vauras J, Nikoskelainen J, Viljanen MK, et al. Semiquantitative detection by real-time PCR of *Aspergillus fumigatus* in bronchoalveolar lavage fluids and tissue biopsy specimens from patients with invasive aspergillosis. *J Clin Microbiol* 2003;41:4304–11.
- [446] Lass-Flörl C, Günsilius E, Gastl G, Bonatti H, Freund MC, Gschwendner A, et al. Diagnosing invasive aspergillosis during antifungal therapy by PCR analysis of blood samples. *J Clin Microbiol* 2004;42:4154–7.
- [447] Musher B, Fredricks D, Leisenring W, Balajee SA, Smith C, Marr KA. *Aspergillus* galactomannan enzyme immunoassay and quantitative PCR for diagnosis of invasive aspergillosis with bronchoalveolar lavage fluid. *J Clin Microbiol* 2004;42:5517–22.
- [448] Khot PD, Ko DL, Hackman RC, Fredricks DN. Development and optimization of quantitative PCR for the diagnosis of invasive aspergillosis with bronchoalveolar lavage fluid. *BMC Infect Dis* 2008;8:73.
- [449] Fréalle E, Decrucq K, Botterel F, Bouchindhomme B, Camus D, Dei-Cas E, et al. Diagnosis of invasive aspergillosis using bronchoalveolar lavage in haematology patients: influence of bronchoalveolar lavage human DNA content on real-time PCR performance. *Eur J Clin Microbiol Infect Dis* 2009;28:223–32.
- [450] Torelli R, Sanguinetti M, Moody A, Pagano L, Caira M, De Carolis E, et al. Diagnosis of invasive aspergillosis by a commercial real-time PCR assay for *Aspergillus* DNA in bronchoalveolar lavage fluid samples from high-risk patients compared to a galactomannan enzyme immunoassay. *J Clin Microbiol* 2011;49:4273–8.
- [451] Buess FM, Cathomas G, Halter J, Junker L, Grendelmeier P, Tamm M, et al. *Aspergillus*-PCR in bronchoalveolar lavage for detection of invasive pulmonary aspergillosis in immunocompromised patients. *BMC Infect Dis* 2012;12:237.
- [452] Reinwald M, Hummel M, Kovalevskaia E, Spiess B, Heinz WJ, Vehreschild JJ, et al. Therapy with antifungals decreases the diagnostic performance of PCR for diagnosing invasive aspergillosis in bronchoalveolar lavage samples of patients with haematological malignancies. *J Antimicrob Chemother* 2012;67:2260–7.
- [453] Orsi CF, Gennari W, Venturelli C, La Regina A, Pecorari M, Righi E, et al. Performance of 2 commercial real-time polymerase chain reaction assays for the detection of *Aspergillus* and *Pneumocystis* DNA in bronchoalveolar lavage fluid samples from critical care patients. *Diagn Microbiol Infect Dis* 2012;73:138–43.
- [454] Guinea J, Padilla C, Escibano P, Muñoz P, Padilla B, Gijen P, et al. Evaluation of mycassay *Aspergillus* for diagnosis of invasive pulmonary aspergillosis in patients without hematological cancer. *PLoS One* 2013;8:e61545.
- [455] Steinmann J, Buer J, Rath PM, Paul A, Saner F. Invasive aspergillosis in two liver transplant recipients: diagnosis by septifast. *Transpl Infect Dis* 2009;11:175–8.
- [456] Komatsu H, Fujisawa T, Inui A, Horiuchi K, Hashizume H, Sogo T, et al. Molecular diagnosis of cerebral aspergillosis by sequence analysis with pan-fungal polymerase chain reaction. *J Pediatr Hematol Oncol* 2004;26:40–4.
- [457] Kami M, Shirouzu I, Mitani K, Ogawa S, Matsumura T, Kanda Y, et al. Early diagnosis of central nervous system aspergillosis with combination use of cerebral diffusion-weighted echo-planar magnetic resonance image and polymerase chain reaction of cerebrospinal fluid. *Intern Med* 1999;38:45–8.
- [458] Hummel M, Spiess B, Kentouche K, Niggemann S, Bihm C, Reuter S, et al. Detection of aspergillus DNA in cerebrospinal fluid from patients with cerebral aspergillosis by a nested PCR assay. *J Clin Microbiol* 2006;44:3989–93.
- [459] Badiie P, Alborzi A. Assessment of a real-time PCR method to detect human non-cryptococcal fungal meningitis. *Arch Iran Med* 2011;14:381–4.
- [460] Mengoli C, Cruciani M, Barnes RA, Loeffler J, Donnelly JP. Use of PCR for diagnosis of invasive aspergillosis: systematic review and meta-analysis. *Lancet Infect Dis* 2009;9:89–96.
- [461] White PL, Mengoli C, Bretagne S, Cuenca-Estrella M, Finnstrom N, Klingspor L, et al. Evaluation of *Aspergillus* PCR protocols for testing serum specimens. *J Clin Microbiol* 2011;49:3842–8.
- [462] White PL, Linton CJ, Perry MD, Johnson EM, Barnes RA. The evolution and evaluation of a whole blood polymerase chain reaction assay for the detection of invasive aspergillosis in hematology patients in a routine clinical setting. *Clin Infect Dis* 2006;42:479–86.
- [463] Lass-Flörl C, Mutschlechner W, Aigner M, Grif K, Marth C, Girschikofsky M, et al. Utility of PCR in diagnosis of invasive fungal infections: real-life data from a multicenter study. *J Clin Microbiol* 2013;51:863–8.
- [464] Paterson PJ, Seaton S, McLaughlin J, Kibbler CC. Development of molecular methods for the identification of *Aspergillus* and emerging moulds in paraffin wax embedded tissue sections. *Mol Pathol* 2003;56:368–70.
- [465] Paterson PJ, Seaton S, McHugh TD, McLaughlin J, Potter M, Prentice HG, et al. Validation and clinical application of molecular methods for the identification of moulds in tissue. *Clin Infect Dis* 2006;42:51–6.
- [466] von Eiff M, Roos N, Schulten R, Hesse M, Zählsdorf M, van de Loo J. Pulmonary aspergillosis: early diagnosis improves survival. *Respiration* 1995;62:341–7.
- [467] Kappe R, Rimek D. Antibody detection in patients with invasive aspergillosis. *Mycoses* 2004;47:59.
- [468] Weig M, Frosch M, Tintelnot K, Haas A, Gross U, Linsmeier B, et al. Use of recombinant mitogillin for improved serodiagnosis of *Aspergillus fumigatus*-associated diseases. *J Clin Microbiol* 2001;39:1721–30.
- [469] Du C, Wingard JR, Cheng S, Nguyen MH, Clancy C. Serum IgG responses against *Aspergillus* proteins before hematopoietic stem cell transplantation or chemotherapy identify patients who develop invasive aspergillosis. *Biol Blood Marrow Transpl* 2012;18:1927–34.
- [470] Holmberg K, Berdischewsky M, Young LS. Serologic immunodiagnosis of invasive aspergillosis. *J Infect Dis* 1980;141:656–64.
- [471] Manso E, Montillo M, De Sio G, D'Amico S, Discepoli G, Leoni P. Value of antigen and antibody detection in the serological diagnosis of invasive aspergillosis in patients with hematological malignancies. *Eur J Clin Microbiol Infect Dis* 1994;13:756–60.
- [472] Mishra SK, Falkenberg S, Masihi KN. Efficacy of enzyme-linked immunosorbent assay in serodiagnosis of aspergillosis. *J Clin Microbiol* 1983;17:708–10.

- [473] Kappe R, Schulze-Berge A, Sonntag HG. Evaluation of eight antibody tests and one antigen test for the diagnosis of invasive aspergillosis. *Mycoses* 1996;39:13–23.
- [474] Fraczek MG, Bromley M, Buied A, Moore CB, Rajendran R, Rautemaa R, et al. The CDR1b efflux transporter is associated with non-cyp51a-mediated itraconazole resistance in *Aspergillus fumigatus*. *J Antimicrob Chemother* 2013;68:1486–96.
- [475] Bueid A, Howard SJ, Moore CB, Richardson MD, Harrison E, Bowyer P, et al. Azole antifungal resistance in *Aspergillus fumigatus*: 2008 and 2009. *J Antimicrob Chemother* 2010;65:2116–8.
- [476] Arendrup MC, Mavridou E, Mortensen KL, Snelders E, Frimodt-Moller N, Khan H, et al. Development of azole resistance in *Aspergillus fumigatus* during azole therapy associated with change in virulence. *PLoS One* 2010;5:e10080.
- [477] van der Linden JW, Jansen RR, Bresters D, Visser CE, Geerlings SE, Kuijper EJ, et al. Azole-resistant central nervous system aspergillosis. *Clin Infect Dis* 2009;48:1111–3.
- [478] Badali H, Vaezi A, Haghani I, Yazdanparast SA, Hedayati MT, Mousavi B, et al. Environmental study of azole-resistant *Aspergillus fumigatus* with tr34/198h mutations in the cyp51a gene in Iran. *Mycoses* 2013;56:659–63.
- [479] Chowdhary A, Kathuria S, Xu J, Sharma C, Sundar G, Singh PK, et al. Clonal expansion and emergence of environmental multiple-triazole-resistant *Aspergillus fumigatus* strains carrying the tr(3)(4)/198h mutations in the cyp51a gene in India. *PLoS One* 2012;7:e52871.
- [480] Mortensen KL, Mellado E, Lass-Flörl C, Rodriguez-Tudela JL, Johansen HK, Arendrup MC. Environmental study of azole-resistant *Aspergillus fumigatus* and other aspergilli in Austria, Denmark, and Spain. *Antimicrob Agents Chemother* 2010;54:4545–9.
- [481] Arendrup MC, Cuenca-Estrella M, Lass-Flörl C, Hope WW. Breakpoints for antifungal agents: an update from EUCAST focussing on echinocandins against *Candida* spp. and triazoles against *Aspergillus* spp. *Drug Resist Updat* 2013;16:81–95.
- [482] Vermeulen E, Maertens J, Schoemans H, Lagrou K. Azole-resistant *Aspergillus fumigatus* due to tr46/y121f/t289a mutation emerging in Belgium, July 2012. *Euro Surveill* 2012;17.
- [483] Chowdhary A, Kathuria S, Randhawa HS, Gaur SN, Klaassen CH, Meis JF. Isolation of multiple-triazole-resistant *Aspergillus fumigatus* strains carrying the tr/198h mutations in the cyp51a gene in India. *J Antimicrob Chemother* 2012;67:362–6.
- [484] Rath PM, Buchheidt D, Spiess B, Arfanis E, Buer J, Steinmann J. First reported case of azole-resistant *Aspergillus fumigatus* due to the tr/198h mutation in Germany. *Antimicrob Agents Chemother* 2012;56:6060–1.
- [485] Balajee SA, Baddley JW, Peterson SW, Nickle D, Varga J, Boey A, et al. *Aspergillus alabamensis*, a new clinically relevant species in the section *terrei*. *Eukaryot Cell* 2009;8:713–22.
- [486] Buil JB, van der Lee HAL, Rijs A, Zoll J, Hovestadt J, Melchers WJG, et al. Single-center evaluation of an agar-based screening for azole resistance in *Aspergillus fumigatus* by using vipcheck. *Antimicrob Agents Chemother* 2017;61:e1250–1217.
- [487] van Leer-Buter C, Takes RP, Hebeda KM, Melchers WJ, Verweij PE. Aspergillosis—and a misleading sensitivity result. *Lancet* 2007;370:102.
- [488] Howard SJ, Pasqualotto AC, Anderson MJ, Leatherbarrow H, Albarrag AM, Harrison E, et al. Major variations in *Aspergillus fumigatus* arising within aspergillomas in chronic pulmonary aspergillosis. *Mycoses* 2013;56:434–41.
- [489] Hope WW, Cuenca-Estrella M, Lass-Flörl C, Arendrup MC. European Committee on Antimicrobial Susceptibility Testing-Subcommittee on Antifungal Susceptibility T. EUCAST technical note on voriconazole and *Aspergillus* spp. *Clin Microbiol Infect* 2013;19:E278–80.
- [490] Arendrup MC, Meletiadis J, Mouton JW, Guinea J, Cuenca-Estrella M, Lagrou K, et al. EUCAST technical note on isavuconazole breakpoints for *Aspergillus*, itraconazole breakpoints for *Candida* and updates for the antifungal susceptibility testing method documents. *Clin Microbiol Infect* 2016;22:571 e571–4.
- [491] Rex JH. Reference method for broth dilution antifungal susceptibility testing of filamentous fungi: approved standard. Wayne, PA: Clinical and Laboratory Standards Institute; 2008.
- [492] Burgel PR, Baixench MT, Amsellem M, Audureau E, Chapron J, Kanaan R, et al. High prevalence of azole-resistant *Aspergillus fumigatus* in adults with cystic fibrosis exposed to itraconazole. *Antimicrob Agents Chemother* 2012;56:869–74.
- [493] Araujo R, Espinel-Ingroff A. Comparison of assessment of oxygen consumption, Etest, and CLSI m38-a2 broth microdilution methods for evaluation of the susceptibility of *Aspergillus fumigatus* to posaconazole. *Antimicrob Agents Chemother* 2009;53:4921–3.
- [494] Arikian S, Sancak B, Alp S, Hascelik G, McNicholas P. Comparative *in vitro* activities of posaconazole, voriconazole, itraconazole, and amphotericin B against *Aspergillus* and *Rhizopus*, and synergy testing for *Rhizopus*. *Med Mycol* 2008;46:567–73.
- [495] Guinea J, Pelaez T, Recio S, Torres-Narbona M, Bouza E. *In vitro* antifungal activities of isavuconazole (bal4815), voriconazole, and fluconazole against 1,007 isolates of zygomycete, *Candida*, *Aspergillus*, *Fusarium*, and *Scedosporium* species. *Antimicrob Agents Chemother* 2008;52:1396–400.
- [496] Howard SJ, Harrison E, Bowyer P, Varga J, Denning DW. Cryptic species and azole resistance in the *Aspergillus niger* complex. *Antimicrob Agents Chemother* 2011;55:4802–9.
- [497] Denning DW, Radford SA, Oakley KL, Hall L, Johnson EM, Warnock DW. Correlation between *in-vitro* susceptibility testing to itraconazole and *in-vivo* outcome of *Aspergillus fumigatus* infection. *J Antimicrob Chemother* 1997;40:401–14.
- [498] Denning DW, Venkateswarlu K, Oakley KL, Anderson MJ, Manning NJ, Stevens DA, et al. Itraconazole resistance in *Aspergillus fumigatus*. *Antimicrob Agents Chemother* 1997;41:1364–8.
- [499] Rudramurthy SM, Chakrabarti A, Geertsens E, Mouton JW, Meis JF. *In vitro* activity of isavuconazole against 208 *Aspergillus flavus* isolates in comparison with 7 other antifungal agents: assessment according to the methodology of the European Committee on Antimicrobial Susceptibility Testing. *Diagn Microbiol Infect Dis* 2011;71:370–7.
- [500] Pfaller MA, Messer SA, Woosley LN, Jones RN, Castanheira M. Echinocandin and triazole antifungal susceptibility profiles for clinical opportunistic yeast and mold isolates collected from 2010 to 2011: application of new CLSI clinical breakpoints and epidemiological cutoff values for characterization of geographic and temporal trends of antifungal resistance. *J Clin Microbiol* 2013;51:2571–81.
- [501] Snelders E, van der Lee HA, Kuijpers J, Rijs AJ, Varga J, Samson RA, et al. Emergence of azole resistance in *Aspergillus fumigatus* and spread of a single resistance mechanism. *PLoS Med* 2008;5:e219.
- [502] Perkhof S, Lechner V, Lass-Flörl C, European Committee on Antimicrobial Susceptibility T. *In vitro* activity of isavuconazole against *Aspergillus* species and zygomycetes according to the methodology of the European Committee on Antimicrobial Susceptibility Testing. *Antimicrob Agents Chemother* 2009;53:1645–7.
- [503] Hodiampont CJ, Dolman KM, Ten Berge IJ, Melchers WJ, Verweij PE, Pajkrt D. Multiple-azole-resistant *Aspergillus fumigatus* osteomyelitis in a patient with chronic granulomatous disease successfully treated with long-term oral posaconazole and surgery. *Med Mycol* 2009;47:217–20.
- [504] Mavridou E, Bruggemann RJ, Melchers WJ, Mouton JW, Verweij PE. Efficacy of posaconazole against three clinical *Aspergillus fumigatus* isolates with mutations in the cyp51a gene. *Antimicrob Agents Chemother* 2010;54:860–5.
- [505] Espinel-Ingroff A, Chowdhary A, Gonzalez GM, Lass-Flörl C, Martin-Mazuelos E, Meis J, et al. Multicenter study of isavuconazole MIC distributions and epidemiological cutoff values for *Aspergillus* spp. For the CLSI m38-a2 broth microdilution method. *Antimicrob Agents Chemother* 2013;57:3823–8.
- [506] Howard SJ, Lass-Flörl C, Cuenca-Estrella M, Gomez-Lopez A, Arendrup MC. Determination of isavuconazole susceptibility of *Aspergillus* and *Candida* species by the EUCAST method. *Antimicrob Agents Chemother* 2013;57:5426–31.
- [507] Gregson L, Goodwin J, Johnson A, McEntee L, Moore CB, Richardson M, et al. *In vitro* susceptibility of *Aspergillus fumigatus* to isavuconazole: correlation with itraconazole, voriconazole, and posaconazole. *Antimicrob Agents Chemother* 2013;57:5778–80.
- [508] Lionakis MS, Lewis RE, Chamilos G, Kontoyiannis DP. *Aspergillus* susceptibility testing in patients with cancer and invasive aspergillosis: difficulties in establishing correlation between *in vitro* susceptibility data and the outcome of initial amphotericin B therapy. *Pharmacotherapy* 2005;25:1174–80.
- [509] Mosquera J, Warn PA, Morrissey J, Moore CB, Gil-Lamaignere C, Denning DW. Susceptibility testing of *Aspergillus flavus*: inoculum dependence with itraconazole and lack of correlation between susceptibility to amphotericin B *in vitro* and outcome *in vivo*. *Antimicrob Agents Chemother* 2001;45:1456–62.
- [510] Barchiesi F, Spreghini E, Sanguinetti M, Giannini D, Manso E, Castelli P, et al. Effects of amphotericin B on *Aspergillus flavus* clinical isolates with variable susceptibilities to the polyene in an experimental model of systemic aspergillosis. *J Antimicrob Chemother* 2013;68:2587–91.
- [511] Hadrich I, Makni F, Neji S, Cheikhrouhou F, Bellaaj H, Elloumi M, et al. Amphotericin B *in vitro* resistance is associated with fatal *Aspergillus flavus* infection. *Med Mycol* 2012;50:829–34.
- [512] Arendrup MC, Cuenca-Estrella M, Lass-Flörl C, Hope WW. European Committee on antimicrobial susceptibility testing subcommittee on antifungal susceptibility T. Eucast technical note on aspergillus and amphotericin B, itraconazole, and posaconazole. *Clin Microbiol Infect* 2012;18:E248–50.
- [513] European Committee on Antimicrobial Susceptibility Testing. Available at: <http://www.eucast.org>.
- [514] Espinel-Ingroff A, Diekema DJ, Fothergill A, Johnson E, Pelaez T, Pfaller MA, et al. Wild-type MIC distributions and epidemiological cutoff values for the triazoles and six *Aspergillus* spp. For the CLSI broth microdilution method (M38-A2 document). *J Clin Microbiol* 2010;48:3251–7.
- [515] Nivoix Y, Velten M, Letscher-Bru V, Moghaddam A, Natarajan-Ame S, Fohrer C, et al. Factors associated with overall and attributable mortality in invasive aspergillosis. *Clin Infect Dis* 2008;47:1176–84.
- [516] Upton A, Kirby KA, Carpenter P, Boeckh M, Marr KA. Invasive aspergillosis following hematopoietic cell transplantation: outcomes and prognostic factors associated with mortality. *Clin Infect Dis* 2007;44:531–40.
- [517] Pagano L, Caira M, Candoni A, Offidani M, Martino B, Specchia G, et al. Invasive aspergillosis in patients with acute myeloid leukemia: a seifem-2008 registry study. *Haematologica* 2010;95:644–50.
- [518] Baddley JW, Andes DR, Marr KA, Kontoyiannis DP, Alexander BD, Kauffman CA, et al. Factors associated with mortality in transplant patients with invasive aspergillosis. *Clin Infect Dis* 2010;50:1559–67.

- [519] Lortholary O, Gangneux JP, Sitbon K, Lebeau B, de Monbrison F, Le Strat Y, et al. Epidemiological trends in invasive aspergillosis in France: the SAIF network (2005–2007). *Clin Microbiol Infect* 2011;17:1882–9.
- [520] Perkhofers S, Lass-Flörl C, Hell M, Russ G, Krause R, Honigl M, et al. The nationwide Austrian aspergillus registry: a prospective data collection on epidemiology, therapy and outcome of invasive mould infections in immunocompromised and/or immunosuppressed patients. *Int J Antimicrob Agents* 2010;36:531–6.
- [521] Lass-Flörl C, Alastruey-Izquierdo A, Cuenca-Estrella M, Perkhofers S, Rodriguez-Tudela JL. In vitro activities of various antifungal drugs against *Aspergillus terreus*: global assessment using the methodology of the European Committee on Antimicrobial Susceptibility Testing. *Antimicrob Agents Chemother* 2009;53:794–5.
- [522] Kathuria S, Sharma C, Singh PK, Agarwal P, Agarwal K, Hagen F, et al. Molecular epidemiology and *in-vitro* antifungal susceptibility of *Aspergillus terreus* species complex isolates in Delhi, India: evidence of genetic diversity by amplified fragment length polymorphism and microsatellite typing. *PLoS One* 2015;10, e0118997.
- [523] Alastruey-Izquierdo A, Cuesta I, Houbraken J, Cuenca-Estrella M, Monzon A, Rodriguez-Tudela JL. In vitro activity of nine antifungal agents against clinical isolates of *Aspergillus calidoustus*. *Med Mycol* 2010;48:97–102.
- [524] Alcazar-Fuoli L, Mellado E, Alastruey-Izquierdo A, Cuenca-Estrella M, Rodriguez-Tudela JL. *Aspergillus* section *fumigati*: antifungal susceptibility patterns and sequence-based identification. *Antimicrob Agents Chemother* 2008;52:1244–51.
- [525] Datta K, Rhee P, Byrnes 3rd E, Garcia-Effron G, Perlin DS, Staab JF, et al. Isavuconazole activity against *Aspergillus lentulus*, *Neosartorya udagawae*, and *Cryptococcus gattii*, emerging fungal pathogens with reduced azole susceptibility. *J Clin Microbiol* 2013;51:3090–3.
- [526] Howard SJ. Multi-resistant aspergillosis due to cryptic species. *Mycopathologia* 2014;178:435–9.
- [527] Falcone EL, Holland SM. Invasive fungal infection in chronic granulomatous disease: insights into pathogenesis and management. *Curr Opin Infect Dis* 2012;25:658–69.
- [528] Segal BH, DeCarlo ES, Kwon-Chung KJ, Malech HL, Gallin JI, Holland SM. *Aspergillus nidulans* infection in chronic granulomatous disease. *Medicine (Balt)* 1998;77:345–54.
- [529] Seyedmousavi S, Bruggemann RJ, Melchers WJ, Rijs AJ, Verweij PE, Mouton JW. Efficacy and pharmacodynamics of voriconazole combined with anidulafungin in azole-resistant invasive aspergillosis. *J Antimicrob Chemother* 2013;68:385–93.
- [530] Seyedmousavi S, Mouton JW, Melchers WJ, Bruggemann RJ, Verweij PE. The role of azoles in the management of azole-resistant aspergillosis: from the bench to the bedside. *Drug Resist Updat* 2014;17:37–50.
- [531] Newton PJ, Harris C, Morris J, Denning DW. Impact of liposomal amphotericin B therapy on chronic pulmonary aspergillosis. *J Infect* 2016;73(5):485–95.
- [532] Verweij PE, Howard SJ, Melchers WJ, Denning DW. Azole-resistance in aspergillus: proposed nomenclature and breakpoints. *Drug Resist Updat* 2009;12:141–7.
- [533] Seyedmousavi S, Melchers WJ, Mouton JW, Verweij PE. Pharmacodynamics and dose-response relationships of liposomal amphotericin B against different azole-resistant *Aspergillus fumigatus* isolates in a murine model of disseminated aspergillosis. *Antimicrob Agents Chemother* 2013;57:1866–71.
- [534] Lepak AJ, Marchillo K, VanHecker J, Andes DR. Impact of *in vivo* triazole and echinocandin combination therapy for invasive pulmonary aspergillosis: enhanced efficacy against cyp51 mutant isolates. *Antimicrob Agents Chemother* 2013;57:5438–47.
- [535] Denning DW. Treatment of invasive aspergillosis. *J Infect* 1994;28(Suppl. 1):25–33.
- [536] Denning DW, Tucker RM, Hanson LH, Stevens DA. Treatment of invasive aspergillosis with itraconazole. *Am J Med* 1989;86:791–800.
- [537] Caillot D, Bassaris H, McGeer A, Arthur C, Prentice HG, Seifert W, et al. Intravenous itraconazole followed by oral itraconazole in the treatment of invasive pulmonary aspergillosis in patients with hematologic malignancies, chronic granulomatous disease, or AIDS. *Clin Infect Dis* 2001;33:e83–90.
- [538] Kim SH, Yim DS, Choi SM, Kwon JC, Han S, Lee DG, et al. Voriconazole-related severe adverse events: clinical application of therapeutic drug monitoring in Korean patients. *Int J Infect Dis* 2011;15:e753–8.
- [539] Ueda K, Nannya Y, Kumano K, Hangaishi A, Takahashi T, Imai Y, et al. Monitoring trough concentration of voriconazole is important to ensure successful antifungal therapy and to avoid hepatic damage in patients with hematological disorders. *Int J Hematol* 2009;89:592–9.
- [540] Smith J, Safdar N, Knasinski V, Simmons W, Bhavnani SM, Ambrose PG, et al. Voriconazole therapeutic drug monitoring. *Antimicrob Agents Chemother* 2006;50:1570–2.
- [541] Pieper S, Kolve H, Gumbinger HG, Goletz G, Wurthwein G, Groll AH. Monitoring of voriconazole plasma concentrations in immunocompromised paediatric patients. *J Antimicrob Chemother* 2012;67:2717–24.
- [542] Mitsani D, Nguyen MH, Shields RK, Toyoda Y, Kwak EJ, Silveira FP, et al. Prospective, observational study of voriconazole therapeutic drug monitoring among lung transplant recipients receiving prophylaxis: factors impacting levels and associations between serum troughs, efficacy, and toxicity. *Antimicrob Agents Chemother* 2012;56:2371–7.
- [543] Siopi M, Mavridou E, Mouton JW, Verweij PE, Zerva L, Meletiadis J. Susceptibility breakpoints and target values for therapeutic drug monitoring of voriconazole and *Aspergillus fumigatus* in an *in vitro* pharmacokinetic/pharmacodynamic model. *J Antimicrob Chemother* 2014;69:1611–9.
- [544] Conte Jr JE, Golden JA, Krishna G, McIver M, Little E, Zurlinden E. Intrapulmonary pharmacokinetics and pharmacodynamics of posaconazole at steady state in healthy subjects. *Antimicrob Agents Chemother* 2009;53:703–7.
- [545] Campoli P, Perlin DS, Kristof AS, White TC, Filler SG, Sheppard DC. Pharmacokinetics of posaconazole within epithelial cells and fungi: insights into potential mechanisms of action during treatment and prophylaxis. *J Infect Dis* 2013;208:1717–28.
- [546] Campoli P, Al Abdallah Q, Robitaille R, Solis NV, Fielhaber JA, Kristof AS, et al. Concentration of antifungal agents within host cell membranes: a new paradigm governing the efficacy of prophylaxis. *Antimicrob Agents Chemother* 2011;55:5732–9.
- [547] Blennow O, Eliasson E, Pettersson T, Pohanka A, Szakos A, El-Serafi I, et al. Posaconazole concentrations in human tissues after allogeneic stem cell transplantation. *Antimicrob Agents Chemother* 2014;58:4941–3.
- [548] Cornely OA, Maertens J, Winston DJ, Perfect J, Ullmann AJ, Walsh TJ, et al. Posaconazole vs. Fluconazole or itraconazole prophylaxis in patients with neutropenia. *N Engl J Med* 2007;356:348–59.
- [549] Rijnders BJ, Cornelissen JJ, Slobbe L, Becker MJ, Doorduyn JK, Hop WC, et al. Aerosolized liposomal amphotericin B for the prevention of invasive pulmonary aspergillosis during prolonged neutropenia: a randomized, placebo-controlled trial. *Clin Infect Dis* 2008;46:1401–8.
- [550] Slobbe L, Boersma E, Rijnders BJ. Tolerability of prophylactic aerosolized liposomal amphotericin-b and impact on pulmonary function: data from a randomized placebo-controlled trial. *Pulm Pharmacol Ther* 2008;21:855–9.
- [551] Mattiuzzi GN, Kantarjian H, Faderl S, Lim J, Kontoyannis D, Thomas D, et al. Amphotericin B lipid complex as prophylaxis of invasive fungal infections in patients with acute myelogenous leukemia and myelodysplastic syndrome undergoing induction chemotherapy. *Cancer* 2004;100:581–9.
- [552] van Burik JA, Ratanatharathorn V, Stepan DE, Miller CB, Lipton JH, Vesole DH, et al. Micafungin versus fluconazole for prophylaxis against invasive fungal infections during neutropenia in patients undergoing hematopoietic stem cell transplantation. *Clin Infect Dis* 2004;39:1407–16.
- [553] Park S, Kim K, Jang JH, Kim SJ, Kim WS, Chung DR, et al. Randomized trial of micafungin versus fluconazole as prophylaxis against invasive fungal infections in hematopoietic stem cell transplant recipients. *J Infect* 2016;73:496–505.
- [554] Cordonnier C, Mohty M, Faucher C, Pautas C, Robin M, Vey N, et al. Safety of a weekly high dose of liposomal amphotericin B for prophylaxis of invasive fungal infection in immunocompromised patients: prophylaxis study. *Int J Antimicrob Agents* 2008;31:135–41.
- [555] Penack O, Schwartz S, Martus P, Reinwald M, Schmidt-Hieber M, Thiel E, et al. Low-dose liposomal amphotericin B in the prevention of invasive fungal infections in patients with prolonged neutropenia: results from a randomized, single-center trial. *Ann Oncol* 2006;17:1306–12.
- [556] Annino L, Chierichini A, Anaclerico B, Finolezzi E, Norata M, Cortese S, et al. Prospective phase II single-center study of the safety of a single very high dose of liposomal amphotericin B for antifungal prophylaxis in patients with acute myeloid leukemia. *Antimicrob Agents Chemother* 2013;57:2596–602.
- [557] Wingard JR, Carter SL, Walsh TJ, Kurtzberg J, Small TN, Baden LR, et al. Randomized, double-blind trial of fluconazole versus voriconazole for prevention of invasive fungal infection after allogeneic hematopoietic cell transplantation. *Blood* 2010;116:5111–8.
- [558] Oren I, Rowe JM, Sprecher H, Tamir A, Benyamini N, Akria L, et al. A prospective randomized trial of itraconazole vs fluconazole for the prevention of fungal infections in patients with acute leukemia and hematopoietic stem cell transplant recipients. *Bone Marrow Transpl* 2006;38:127–34.
- [559] Glasmacher A, Cornely O, Ullmann AJ, Wedding U, Bodenstein H, Wandt H, et al. An open-label randomized trial comparing itraconazole oral solution with fluconazole oral solution for primary prophylaxis of fungal infections in patients with hematological malignancy and profound neutropenia. *J Antimicrob Chemother* 2006;57:317–25.
- [560] Marr KA, Crippa F, Leisenring W, Hoyle M, Boeckh M, Balajee SA, et al. Itraconazole versus fluconazole for prevention of fungal infections in patients receiving allogeneic stem cell transplants. *Blood* 2004;103:1527–33.
- [561] Cornely OA, Leguay T, Maertens J, Vehreschild M, Anagnostopoulos A, Castagnola C, et al. Randomized comparison of liposomal amphotericin B versus placebo to prevent invasive mycoses in acute lymphoblastic leukaemia. *J Antimicrob Chemother* 2017;72:2359–67.
- [562] Marks DI, Pagiucca A, Kibbler CC, Glasmacher A, Heussel CP, Kantecki M, et al. Voriconazole versus itraconazole for antifungal prophylaxis following allogeneic haematopoietic stem-cell transplantation. *Br J Haematol* 2011;155:318–27.
- [563] Ullmann AJ, Lipton JH, Vesole DH, Chandrasekar P, Langston A, Tarantolo SR, et al. Posaconazole or fluconazole for prophylaxis in severe graft-versus-host disease. *N Engl J Med* 2007;356:335–47.
- [564] Mellinghoff SC, Bassetti M, Dorfel D, Hagel S, Lehnert N, Plis A, et al. Isavuconazole shortens the QTc interval. *Mycoses* 2018;00:1–5.
- [565] Cornely OA. Isavuconazole: is there a need for a new antifungal? *J Antimicrob Chemother* 2017;72:i2–4.

- [566] Neofytos D, Ostrand D, Shoham S, Laverdiere M, Hiemenz J, Nguyen H, et al. Voriconazole therapeutic drug monitoring: results of a prematurely discontinued randomized multicenter trial. *Transpl Infect Dis* 2015;17: 831–7.
- [567] Herbrecht R, Maertens J, Baila L, Aoun M, Heinz W, Martino R, et al. Caspofungin first-line therapy for invasive aspergillosis in allogeneic hematopoietic stem cell transplant patients: a European organisation for research and treatment of cancer study. *Bone Marrow Transpl* 2010;45:1227–33.
- [568] Viscoli C, Herbrecht R, Akan H, Baila L, Sonet A, Gallamini A, et al. An aortic phase II study of caspofungin as first-line therapy of invasive aspergillosis in haematological patients. *J Antimicrob Chemother* 2009;64:1274–81.
- [569] Cornely OA, Vehreschild JJ, Vehreschild MJ, Wurthwein G, Arenz D, Schwartz S, et al. Phase II dose escalation study of caspofungin for invasive aspergillosis. *Antimicrob Agents Chemother* 2011;55:5798–803.
- [570] Ito JI, Chandrasekar PH, Hooshmand-Rad R. Effectiveness of amphotericin B lipid complex (ABLC) treatment in allogeneic hematopoietic cell transplant (hct) recipients with invasive aspergillosis (IA). *Bone Marrow Transpl* 2005;36:873–7.
- [571] Kohno S, Masaoka T, Yamaguchi H, Mori T, Urabe A, Ito A, et al. A multicenter, open-label clinical study of micafungin (FK463) in the treatment of deep-seated mycosis in Japan. *Scand J Infect Dis* 2004;36:372–9.
- [572] Denning DW, Marr KA, Lau WM, Facklam DP, Ratanatharathorn V, Becker C, et al. Micafungin (FK463), alone or in combination with other systemic antifungal agents, for the treatment of acute invasive aspergillosis. *J Infect* 2006;53:337–49.
- [573] Kontoyiannis DP, Ratanatharathorn V, Young JA, Raymond J, Laverdiere M, Denning DW, et al. Micafungin alone or in combination with other systemic antifungal therapies in hematopoietic stem cell transplant recipients with invasive aspergillosis. *Transpl Infect Dis* 2009;11:89–93.
- [574] Caillot D, Thiebaut A, Herbrecht R, de Botton S, Pigneux A, Bernard F, et al. Liposomal amphotericin B in combination with caspofungin for invasive aspergillosis in patients with hematologic malignancies: a randomized pilot study (cambistrat trial). *Cancer* 2007;110:2740–6.
- [575] Dohen-Becue F, Salez F, Ramon P, Leblond-Tillie I, Wallaert B, Bauters A, et al. Management of hemoptysis in invasive pulmonary aspergillosis. *Rev Maladies Resp* 1998;15:791–6.
- [576] Schwartz S, Ruhnke M, Ribaud P, Corey L, Driscoll T, Cornely OA, et al. Improved outcome in central nervous system aspergillosis, using voriconazole treatment. *Blood* 2005;106:2641–5.
- [577] Kourkoumpetis TK, Desalermos A, Muhammed M, Mylonakis E. Central nervous system aspergillosis: a series of 14 cases from a general hospital and review of 123 cases from the literature. *Medicine (Balt)* 2012;91:328–36.
- [578] Rüping MJ, Albermann N, Ebinger F, Burckhardt I, Beisel C, Muller C, et al. Posaconazole concentrations in the central nervous system. *J Antimicrob Chemother* 2008;62:1468–70.
- [579] Coleman JM, Hogg GG, Rosenfeld JV, Waters KD. Invasive central nervous system aspergillosis: cure with liposomal amphotericin B, itraconazole, and radical surgery—case report and review of the literature. *Neurosurgery* 1995;36:858–63.
- [580] Clemons KV, Espiritu M, Parmar R, Stevens DA. Comparative efficacies of conventional amphotericin B, liposomal amphotericin B (ambisome), caspofungin, micafungin, and voriconazole alone and in combination against experimental murine central nervous system aspergillosis. *Antimicrob Agents Chemother* 2005;49:4867–75.
- [581] Ellis M, Spence D, de Pauw B, Meunier F, Marinus A, Collette L, et al. An EORTC international multicenter randomized trial (EORTC number 19923) comparing two dosages of liposomal amphotericin B for treatment of invasive aspergillosis. *Clin Infect Dis* 1998;27:1406–12.
- [582] Schwartz S, Ruhnke M, Ribaud P, Reed E, Troke P, Thiel E. Poor efficacy of amphotericin b-based therapy in CNS aspergillosis. *Mycoses* 2007;50: 196–200.
- [583] Ullmann AJ, Sanz MA, Tramarin A, Barnes RA, Wu W, Gerlach BA, et al. Prospective study of amphotericin B formulations in immunocompromised patients in 4 European countries. *Clin Infect Dis* 2006;43:e29–38.
- [584] Wingard JR, Kubilis P, Lee L, Yee G, White M, Walshe L, et al. Clinical significance of nephrotoxicity in patients treated with amphotericin B for suspected or proven aspergillosis. *Clin Infect Dis* 1999;29:1402–7.
- [585] Girmenia C, Pizzarelli G, Pozzi E, Cimino G, Gentile G, Martino P. Improving outcomes of acute invasive aspergillus rhinosinusitis in patients with hematologic malignancies or aplastic anemia: the role of voriconazole. *Haematologica* 2008;93:159–60.
- [586] Thurtell MJ, Chiu AL, Goold LA, Akdal G, Crompton JL, Ahmed R, et al. Neuro-ophthalmology of invasive fungal sinusitis: 14 consecutive patients and a review of the literature. *Clin Exp Ophthalmol* 2013;41:567–76.
- [587] Daudia A, Jones NS. Advances in management of paranasal sinus aspergillosis. *J Laryngol Otol* 2008;122:331–5.
- [588] Boogaerts M, Winston DJ, Bow EJ, Garber G, Reboli AC, Schwarzer AP, et al. Intravenous and oral itraconazole versus intravenous amphotericin B deoxycholate as empirical antifungal therapy for persistent fever in neutropenic patients with cancer who are receiving broad-spectrum antibacterial therapy. A randomized, controlled trial. *Ann Intern Med* 2001;135: 412–22.
- [589] Wingard JR, White MH, Anaissie E, Raffalli J, Goodman J, Arrieta A, et al. A randomized, double-blind comparative trial evaluating the safety of liposomal amphotericin B versus amphotericin B lipid complex in the empirical treatment of febrile neutropenia. L amph/abc collaborative study group. *Clin Infect Dis* 2000;31:1155–63.
- [590] White MH, Bowden RA, Sandler ES, Graham ML, Noskin GA, Wingard JR, et al. Randomized, double-blind clinical trial of amphotericin B colloidal dispersion vs. Amphotericin B in the empirical treatment of fever and neutropenia. *Clin Infect Dis* 1998;27:296–302.
- [591] Tamura K, Urabe A, Yoshida M, Kanamaru A, Kodera Y, Okamoto S, et al. Efficacy and safety of micafungin, an echinocandin antifungal agent, on invasive fungal infections in patients with hematological disorders. *Leuk Lymphoma* 2009;50:92–100.
- [592] Lass-Flörl C. Triazole antifungal agents in invasive fungal infections: a comparative review. *Drugs* 2011;71:2405–19.
- [593] Luong ML, Chaparro C, Stephenson A, Rotstein C, Singer LG, Waters V, et al. Pretransplant aspergillus colonization of cystic fibrosis patients and the incidence of post-lung transplant invasive aspergillosis. *Transplantation* 2014;97:351–7.
- [594] Monforte V, Roman A, Gavalda J, Bravo C, Tenorio L, Ferrer A, et al. Nebulized amphotericin B prophylaxis for aspergillus infection in lung transplantation: study of risk factors. *J Heart Lung Transpl* 2001;20:1274–81.
- [595] Iversen M, Burton CM, Vand S, Skovfoged L, Carlsen J, Milman N, et al. *Aspergillus* infection in lung transplant patients: incidence and prognosis. *Eur J Clin Microbiol Infect Dis* 2007;26:879–86.
- [596] Hsu JL, Khan MA, Sobel RA, Jiang X, Clemons KV, Nguyen TT, et al. *Aspergillus fumigatus* invasion increases with progressive airway ischemia. *PLoS One* 2013;8, e77136.
- [597] Sole A, Morant P, Salavert M, Peman J, Morales P, Valencia Lung Transplant G. *Aspergillus* infections in lung transplant recipients: risk factors and outcome. *Clin Microbiol Infect* 2005;11:359–65.
- [598] Danziger-Isakov LA, Worley S, Arrigain S, Aurora P, Ballmann M, Boyer D, et al. Increased mortality after pulmonary fungal infection within the first year after pediatric lung transplantation. *J Heart Lung Transpl* 2008;27: 655–61.
- [599] Sarmiento E, Rodriguez-Molina JJ, Fernandez-Yanez J, Palomo J, Urrea R, Munoz P, et al. Igg monitoring to identify the risk for development of infection in heart transplant recipients. *Transpl Infect Dis* 2006;8:49–53.
- [600] Fortun J, Martin-Davila P, Sanchez MA, Pintado V, Alvarez ME, Sanchez-Sousa A, et al. Voriconazole in the treatment of invasive mold infections in transplant recipients. *Eur J Clin Microbiol Infect Dis* 2003;22:408–13.
- [601] Collins LA, Samore MH, Roberts MS, Luzzati R, Jenkins RL, Lewis WD, et al. Risk factors for invasive fungal infections complicating orthotopic liver transplantation. *J Infect Dis* 1994;170:644–52.
- [602] Singh N, Husain S, Practice ASTIDCo. Invasive aspergillosis in solid organ transplant recipients. *Am J Transpl* 2009;9(Suppl. 4):S180–91.
- [603] Singh N, Pruett TL, Houston S, Munoz P, Cacciarelli TV, Wagener MM, et al. Invasive aspergillosis in the recipients of liver retransplantation. *Liver Transpl* 2006;12:1205–9.
- [604] Saliba F, Delvart V, Ichai P, Kassis N, Botterel F, Mihaila L, et al. Fungal infections after liver transplantation: outcomes and risk factors revisited in the meld era. *Clin Transpl* 2013;27:E454–61.
- [605] He H, Ding L, Li F, Zhan Q. Clinical features of invasive bronchial-pulmonary aspergillosis in critically ill patients with chronic obstructive respiratory diseases: a prospective study. *Crit Care* 2011;15:R5.
- [606] Bulpa P, Dive A, Sibille Y. Invasive pulmonary aspergillosis in patients with chronic obstructive pulmonary disease. *Eur Respir J* 2007;30:782–800.
- [607] Kistemann T, Huneburg H, Exner M, Vacata V, Engelhart S. Role of increased environmental aspergillus exposure for patients with chronic obstructive pulmonary disease (COPD) treated with corticosteroids in an intensive care unit. *Int J Hyg Environ Health* 2002;204:347–51.
- [608] Murray CK, Loo FL, Hospenthal DR, Cancio LC, Jones JA, Kim SH, et al. Incidence of systemic fungal infection and related mortality following severe burns. *Burns* 2008;34:1108–12.
- [609] Lahmer T, Messer M, Schwerdtfeger C, Rasch S, Lee M, Saugel B, et al. Invasive mycosis in medical intensive care unit patients with severe alcoholic hepatitis. *Mycopathologia* 2014;177:193–7.
- [610] Ballard J, Edelman L, Saffle J, Sheridan R, Kagan R, Bracco D, et al. Positive fungal cultures in burn patients: a multicenter review. *J Burn Care Res* 2008;29:213–21.
- [611] Horvath EE, Murray CK, Vaughan GM, Chung KK, Hospenthal DR, Wade CE, et al. Fungal wound infection (not colonization) is independently associated with mortality in burn patients. *Ann Surg* 2007;245:978–85.
- [612] He H, Ding L, Sun B, Li F, Zhan Q. Role of galactomannan determinations in bronchoalveolar lavage fluid samples from critically ill patients with chronic obstructive pulmonary disease for the diagnosis of invasive pulmonary aspergillosis: a prospective study. *Crit Care* 2012;16:R138.
- [613] Khorvash F, Meidani M, Babaei L, Abbasi S, Atefi B, Yaran M. Galactomannan antigen assay from bronchoalveolar lavage fluid in diagnosis of invasive pulmonary aspergillosis in intensive care units patients. *Adv Biomed Res* 2014;3:68.
- [614] Steinmann J, Buer J, Rath PM. Detection of *Aspergillus fumigatus* in blood samples from critically ill patients in intensive care units by use of the septifast assay. *J Clin Microbiol* 2016;54:1918–21.
- [615] Westh H, Lisby G, Breyse F, Boddinghaus B, Chomarar M, Gant V, et al. Multiplex real-time PCR and blood culture for identification of bloodstream pathogens in patients with suspected sepsis. *Clin Microbiol Infect* 2009;15: 544–51.

- [616] Clancy CJ, Jaber RA, Leather HL, Wingard JR, Staley B, Wheat LJ, et al. Bronchoalveolar lavage galactomannan in diagnosis of invasive pulmonary aspergillosis among solid-organ transplant recipients. *J Clin Microbiol* 2007;45:1759–65.
- [617] Gazzoni FF, Hochhegger B, Severo LC, Marchiori E, Pasqualotto A, Sartori AP, et al. High-resolution computed tomographic findings of *Aspergillus* infection in lung transplant patients. *Eur J Radiol* 2014;83:79–83.
- [618] Alexander BD, Smith PB, Davis RD, Perfect JR, Reller LB. The (1,3)- β -D-glucan test as an aid to early diagnosis of invasive fungal infections following lung transplantation. *J Clin Microbiol* 2010;48:4083–8.
- [619] Husain S, Paterson DL, Studer SM, Crespo M, Pilewski J, Durkin M, et al. *Aspergillus* galactomannan antigen in the bronchoalveolar lavage fluid for the diagnosis of invasive aspergillosis in lung transplant recipients. *Transplantation* 2007;83:1330–6.
- [620] Ambrosioni J, Coll S, Manzano C, Nicolas D, Aguero F, Blanco JL, et al. Voriconazole and cobicistat-boosted antiretroviral salvage regimen co-administration to treat invasive aspergillosis in an HIV-infected patient. *J Antimicrob Chemother* 2016;71:1125–7.
- [621] Utili R, Zampino R, De Vivo F, Maiello C, Andreana A, Mormone G, et al. Improved outcome of pulmonary aspergillosis in heart transplant recipients with early diagnosis and itraconazole treatment. *Clin Transpl* 2000;14:282–6.
- [622] Wieland T, Liebold A, Jagiello M, Retzl G, Birnbaum DE. Superiority of voriconazole over amphotericin B in the treatment of invasive aspergillosis after heart transplantation. *J Heart Lung Transpl* 2005;24:102–4.
- [623] Veroux M, Corona D, Gagliano M, Sorbello M, Macarone M, Cutuli M, et al. Voriconazole in the treatment of invasive aspergillosis in kidney transplant recipients. *Transpl Proc* 2007;39:1838–40.
- [624] Baden LR, Katz JT, Fishman JA, Koziol C, DelVecchio A, Doran M, et al. Salvage therapy with voriconazole for invasive fungal infections in patients failing or intolerant to standard antifungal therapy. *Transplantation* 2003;76:1632–7.
- [625] Husain S, Capitano B, Corcoran T, Studer SM, Crespo M, Johnson B, et al. Intrapulmonary disposition of amphotericin B after aerosolized delivery of amphotericin B lipid complex (ABELCET; ABLC) in lung transplant recipients. *Transplantation* 2010;90:1215–9.
- [626] Mucha K, Foronczewicz B, Orlowski T, Religioni J, Bobek-Billewicz B, Jarzab B, et al. Atypical presentation of invasive pulmonary aspergillosis in a liver transplant recipient. *Ann Transpl* 2013;18:238–42.
- [627] Lopez-Medrano F, Fernandez-Ruiz M, Silva JT, Carver PL, van Delden C, Merino E, et al. Clinical presentation and determinants of mortality of invasive pulmonary aspergillosis in kidney transplant recipients: a multinational cohort study. *Am J Transpl* 2016;16:3220–34.
- [628] Chandrasekar PH, Ito JI. Amphotericin B lipid complex in the management of invasive aspergillosis in immunocompromised patients. *Clin Infect Dis* 2005;40(Suppl. 6):S392–400.
- [629] Kleinberg M. Aspergillosis in the clear outcomes trial: working toward a real-world clinical perspective. *Med Mycol* 2005;43(Suppl. 1):S289–94.
- [630] Linden PK, Coley K, Fontes P, Fung JJ, Kusne S. Invasive aspergillosis in liver transplant recipients: outcome comparison of therapy with amphotericin B lipid complex and a historical cohort treated with conventional amphotericin B. *Clin Infect Dis* 2003;37:17–25.
- [631] Groetzner J, Kaczmarek I, Wittwer T, Strauch J, Meiser B, Wahlers T, et al. Caspofungin as first-line therapy for the treatment of invasive aspergillosis after thoracic organ transplantation. *J Heart Lung Transpl* 2008;27:1–6.
- [632] Winkler M, Pratschke J, Schulz U, Zheng S, Zhang M, Li W, et al. Caspofungin for post solid organ transplant invasive fungal disease: results of a retrospective observational study. *Transpl Infect Dis* 2010;12:230–7.
- [633] Maertens J, Egerer G, Shin WS, Reichert D, Stek M, Chandwani S, et al. Caspofungin use in daily clinical practice for treatment of invasive aspergillosis: results of a prospective observational registry. *BMC Infect Dis* 2010;10:182.
- [634] Walter J, Sobotta I, Rogiers X, Broering D, Fischer L. Invasive aspergillosis caused by *Aspergillus terreus* in a living donor liver transplant recipient successfully treated by caspofungin. *Mycoses* 2011;54:e220–2.
- [635] Aguilar-Guisado M, Givalda J, Ussetti P, Ramos A, Morales P, Blanes M, et al. Pneumonia after lung transplantation in the resitra cohort: a multicenter prospective study. *Am J Transpl* 2007;7:1989–96.
- [636] Neoh CF, Snell GI, Levvey B, Kotsimbos T, Morrissey CO, Slavin MA, et al. Preemptive treatment with voriconazole in lung transplant recipients. *Transpl Infect Dis* 2013;15:344–53.
- [637] Drew RH, Dodds Ashley E, Benjamin Jr DK, Duane Davis R, Palmer SM, Perfect JR. Comparative safety of amphotericin B lipid complex and amphotericin B deoxycholate as aerosolized antifungal prophylaxis in lung-transplant recipients. *Transplantation* 2004;77:232–7.
- [638] Monforte V, Ussetti P, Gavalda J, Bravo C, Laporta R, Len O, et al. Feasibility, tolerability, and outcomes of nebulized liposomal amphotericin B for *Aspergillus* infection prevention in lung transplantation. *J Heart Lung Transpl* 2010;29:523–30.
- [639] Monforte V, Lopez-Sanchez A, Zurbano F, Ussetti P, Sole A, Casals C, et al. Prophylaxis with nebulized liposomal amphotericin B for *Aspergillus* infection in lung transplant patients does not cause changes in the lipid content of pulmonary surfactant. *J Heart Lung Transpl* 2013;32:313–9.
- [640] Borro JM, Sole A, de la Torre M, Pastor A, Fernandez R, Saura A, et al. Efficiency and safety of inhaled amphotericin B lipid complex (ABELCET) in the prophylaxis of invasive fungal infections following lung transplantation. *Transpl Proc* 2008;40:3090–3.
- [641] Williams K, Mansh M, Chin-Hong P, Singer J, Arron ST. Voriconazole-associated cutaneous malignancy: a literature review on photocarcinogenesis in organ transplant recipients. *Clin Infect Dis* 2014;58:997–1002.
- [642] Montoya JG, Chaparro SV, Celis D, Cortes JA, Leung AN, Robbins RC, et al. Invasive aspergillosis in the setting of cardiac transplantation. *Clin Infect Dis* 2003;37(Suppl. 3):S281–92.
- [643] Paniagua Martin MJ, Marzoa Rivas R, Barge Caballero E, Grille Cancela Z, Fernandez CJ, Solla M, et al. Efficacy and tolerance of different types of prophylaxis for prevention of early aspergillosis after heart transplantation. *Transpl Proc* 2010;42:3014–6.
- [644] Singh N, Paterson DL, Gayowski T, Wagener MM, Marino IR. Preemptive prophylaxis with a lipid preparation of amphotericin B for invasive fungal infections in liver transplant recipients requiring renal replacement therapy. *Transplantation* 2001;71:910–3.
- [645] Castroagudin JF, Ponton C, Bustamante M, Otero E, Martinez J, Tome S, et al. Prospective interventional study to evaluate the efficacy and safety of liposomal amphotericin B as prophylaxis of fungal infections in high-risk liver transplant recipients. *Transpl Proc* 2005;37:3965–7.
- [646] Reed A, Herndon JB, Ersoz N, Fujikawa T, Schain D, Lipori P, et al. Effect of prophylaxis on fungal infection and costs for high-risk liver transplant recipients. *Liver Transpl* 2007;13:1743–50.
- [647] Fortun J, Martin-Davila P, Montejo M, Munoz P, Cisneros JM, Ramos A, et al. Prophylaxis with caspofungin for invasive fungal infections in high-risk liver transplant recipients. *Transplantation* 2009;87:424–35.
- [648] Winston DJ, Maziarz RT, Chandrasekar PH, Lazarus HM, Goldman M, Blumer JL, et al. Intravenous and oral itraconazole versus intravenous and oral fluconazole for long-term antifungal prophylaxis in allogeneic hematopoietic stem-cell transplant recipients. A multicenter, randomized trial. *Ann Int Med* 2003;138:705–13.
- [649] Marr KA, Leisenring W, Crippa F, Slattery JT, Corey L, Boeckh M, et al. Cyclophosphamide metabolism is affected by azole antifungals. *Blood* 2004;103:1557–9.
- [650] Menichetti F, Del Favero A, Martino P, Bucaneve G, Micozzi A, Girmenia C, et al. Itraconazole oral solution as prophylaxis for fungal infections in neutropenic patients with hematologic malignancies: a randomized, placebo-controlled, double-blind, multicenter trial. Gimema infection program. Gruppo italiano Malattie Ematologiche dell' Adulto. *Clin Infect Dis* 1999;28:250–5.
- [651] Prentice HG, Caillet D, Dupont B, Menichetti F, Schuler U. Oral and intravenous itraconazole for systemic fungal infections in neutropenic haematological patients: meeting report. London, United Kingdom, 20 June 1998, vol. 101. *Acta Haematol*; 1999. p. 56–62.
- [652] Housseau JL, Dekker AW, Stamatoullas-Bastard A, Fassas A, Linkesch W, Gouveia J, et al. Itraconazole oral solution for primary prophylaxis of fungal infections in patients with hematological malignancy and profound neutropenia: a randomized, double-blind, double-placebo, multicenter trial comparing itraconazole and amphotericin B. *Antimicrob Agents Chemother* 2000;44:1887–93.
- [653] Gallin JI, Alling DW, Malech HL, Wesley R, Koziol D, Marciano B, et al. Itraconazole to prevent fungal infections in chronic granulomatous disease. *N Engl J Med* 2003;348:2416–22.
- [654] de Repentigny L, Ratelle J, Leclerc JM, Cornu G, Sokal EM, Jacqmin P, et al. Repeated-dose pharmacokinetics of an oral solution of itraconazole in infants and children. *Antimicrob Agents Chemother* 1998;42:404–8.
- [655] Groll AH, Wood L, Roden M, Mickiene D, Chiou CC, Townley E, et al. Safety, pharmacokinetics, and pharmacodynamics of cyclodextrin itraconazole in pediatric patients with oropharyngeal candidiasis. *Antimicrob Agents Chemother* 2002;46:2554–63.
- [656] Foot AB, Veys PA, Gibson BE. Itraconazole oral solution as antifungal prophylaxis in children undergoing stem cell transplantation or intensive chemotherapy for haematological disorders. *Bone Marrow Transpl* 1999;24:1089–93.
- [657] Simon A, Besuden M, Vezmar S, Hasan C, Lampe D, Kreutzberg S, et al. Itraconazole prophylaxis in pediatric cancer patients receiving conventional chemotherapy or autologous stem cell transplants. *Support Care Cancer* 2007;15:213–20.
- [658] Ananda-Rajah MR, Grigg A, Downey MT, Bajel A, Spelman T, Cheng A, et al. Comparative clinical effectiveness of prophylactic voriconazole/posaconazole to fluconazole/itraconazole in patients with acute myeloid leukemia/myelodysplastic syndrome undergoing cytotoxic chemotherapy over a 12-year period. *Haematologica* 2012;97:459–63.
- [659] Ananda-Rajah MR, Grigg A, Slavin MA. Making sense of posaconazole therapeutic drug monitoring: a practical approach. *Curr Opin Infect Dis* 2012;25:605–11.
- [660] Krishna G, Martinho M, Chandrasekar P, Ullmann AJ, Patino H. Pharmacokinetics of oral posaconazole in allogeneic hematopoietic stem cell transplant recipients with graft-versus-host disease. *Pharmacotherapy* 2007;27:1627–36.
- [661] Welzen ME, Bruggemann RJ, Van Den Berg JM, Voogt HW, Gilissen JH, Pajkrt D, et al. A twice daily posaconazole dosing algorithm for children with chronic granulomatous disease. *Pediatr Infect Dis J* 2011;30:794–7.
- [662] Döring M, Müller C, Johann PD, Erbacher A, Kimmig A, Schwarze CP, et al. Analysis of posaconazole as oral antifungal prophylaxis in pediatric patients under 12 years of age following allogeneic stem cell transplantation. *BMC Infect Dis* 2012;12:263.

- [663] Lehrnbecher T, Attarbaschi A, Duerken M, Garbino J, Gruhn B, Kontny U, et al. Posaconazole salvage treatment in paediatric patients: a multicentre survey. *Eur J Clin Microbiol Infect Dis* 2010;29:1043–5.
- [664] Vanstraelen K, Colita A, Bica AM, Mols R, Augustijns P, Peersman N, et al. Pharmacokinetics of posaconazole oral suspension in children dosed according to body surface area. *Pediatr Infect Dis J* 2016;35:183–8.
- [665] Mattiuzzi GN, Cortes J, Alvarado G, Verstovsek S, Koller C, Pierce S, et al. Efficacy and safety of intravenous voriconazole and intravenous itraconazole for antifungal prophylaxis in patients with acute myelogenous leukemia or high-risk myelodysplastic syndrome. *Support Care Cancer* 2011;19:19–26.
- [666] Barreto JN, Beach CL, Wolf RC, Merten JA, Tosh PK, Wilson JW, et al. The incidence of invasive fungal infections in neutropenic patients with acute leukemia and myelodysplastic syndromes receiving primary antifungal prophylaxis with voriconazole. *Am J Hematol* 2013;88:283–8.
- [667] Walsh TJ, Karlsson MO, Driscoll T, Arguedas AG, Adamson P, Saez-Llorens X, et al. Pharmacokinetics and safety of intravenous voriconazole in children after single- or multiple-dose administration. *Antimicrob Agents Chemother* 2004;48:2166–72.
- [668] Karlsson MO, Lutsar I, Milligan PA. Population pharmacokinetic analysis of voriconazole plasma concentration data from pediatric studies. *Antimicrob Agents Chemother* 2009;53:935–44.
- [669] Driscoll TA, Frangoul H, Nemecek ER, Murphey DK, Yu LC, Blumer J, et al. Comparison of pharmacokinetics and safety of voriconazole intravenous-to-oral switch in immunocompromised adolescents and healthy adults. *Antimicrob Agents Chemother* 2011;55:5780–9.
- [670] Driscoll TA, Yu LC, Frangoul H, Krance RA, Nemecek E, Blumer J, et al. Comparison of pharmacokinetics and safety of voriconazole intravenous-to-oral switch in immunocompromised children and healthy adults. *Antimicrob Agents Chemother* 2011;55:5770–9.
- [671] Molina JR, Serrano J, Sanchez-Garcia J, Rodriguez-Villa A, Gomez P, Tallon D, et al. Voriconazole as primary antifungal prophylaxis in children undergoing allo-sct. *Bone Marrow Transpl* 2012;47:562–7.
- [672] Tollemar J, Ringden O, Andersson S, Sundberg B, Ljungman P, Sparrelid E, et al. Prophylactic use of liposomal amphotericin B (ambisome) against fungal infections: a randomized trial in bone marrow transplant recipients. *Transpl Proc* 1993;25:1495–7.
- [673] Tollemar J, Ringden O, Andersson S, Sundberg B, Ljungman P, Tyden G. Randomized double-blind study of liposomal amphotericin B (ambisome) prophylaxis of invasive fungal infections in bone marrow transplant recipients. *Bone Marrow Transpl* 1993;12:577–82.
- [674] Kelsey SM, Goldman JM, McCann S, Newland AC, Scarffe JH, Oppenheim BA, et al. Liposomal amphotericin (ambisome) in the prophylaxis of fungal infections in neutropenic patients: a randomised, double-blind, placebo-controlled study. *Bone Marrow Transpl* 1999;23:163–8.
- [675] Hong Y, Shaw PJ, Nath CE, Yadav SP, Stephen KR, Earl JW, et al. Population pharmacokinetics of liposomal amphotericin B in pediatric patients with malignant diseases. *Antimicrob Agents Chemother* 2006;50:935–42.
- [676] Ringden O, Meunier J, Tollemar J, Ricci P, Tura S, Kuse E, et al. Efficacy of amphotericin B encapsulated in liposomes (ambisome) in the treatment of invasive fungal infections in immunocompromised patients. *J Antimicrob Chemother* 1991;28(Suppl. B):73–82.
- [677] Kolve H, Ahlke E, Fegeler W, Ritter J, Jurgens H, Groll AH. Safety, tolerance and outcome of treatment with liposomal amphotericin B in paediatric patients with cancer or undergoing haematopoietic stem cell transplantation. *J Antimicrob Chemother* 2009;64:383–7.
- [678] Huang X, Chen H, Han M, Zou P, Wu D, Lai Y, et al. Multicenter, randomized, open-label study comparing the efficacy and safety of micafungin versus itraconazole for prophylaxis of invasive fungal infections in patients undergoing hematopoietic stem cell transplant. *Biol Blood Marrow Transpl* 2012;18:1509–16.
- [679] Seibel NL, Schwartz C, Arrieta A, Flynn P, Shad A, Albano E, et al. Safety, tolerability, and pharmacokinetics of micafungin (FK463) in febrile neutropenic pediatric patients. *Antimicrob Agents Chemother* 2005;49:3317–24.
- [680] Hope WW, Seibel NL, Schwartz CL, Arrieta A, Flynn P, Shad A, et al. Population pharmacokinetics of micafungin in pediatric patients and implications for antifungal dosing. *Antimicrob Agents Chemother* 2007;51:3714–9.
- [681] Arrieta AC, Maddison P, Groll AH. Safety of micafungin in pediatric clinical trials. *Pediatr Infect Dis J* 2011;30:e97–102.
- [682] Mehta PA, Vinks AA, Filipovich A, Bleesing J, Jodele S, Jordan MB, et al. Alternate-day micafungin antifungal prophylaxis in pediatric patients undergoing hematopoietic stem cell transplantation: a pharmacokinetic study. *Biol Blood Marrow Transpl* 2010;16:1458–62.
- [683] Beaute J, Obenga G, Le Mignot L, Mahlaoui N, Bougnoux ME, Mouy R, et al. Epidemiology and outcome of invasive fungal diseases in patients with chronic granulomatous disease: a multicenter study in France. *Pediatr Infect Dis J* 2011;30:57–62.
- [684] Mouy R, Veber F, Blanche S, Donadieu J, Brauner R, Levron JC, et al. Long-term itraconazole prophylaxis against *Aspergillus* infections in thirty-two patients with chronic granulomatous disease. *J Pediatr* 1994;125:998–1003.
- [685] Walsh TJ, Driscoll T, Milligan PA, Wood ND, Schlamm H, Groll AH, et al. Pharmacokinetics, safety, and tolerability of voriconazole in immunocompromised children. *Antimicrob Agents Chemother* 2010;54:4116–23.
- [686] Doby EH, Benjamin Jr DK, Blaschke AJ, Ward RM, Pavia AT, Martin PL, et al. Therapeutic monitoring of voriconazole in children less than three years of age: a case report and summary of voriconazole concentrations for ten children. *Pediatr Infect Dis J* 2012;31:632–5.
- [687] Soler-Palacin P, Frick MA, Martin-Nalda A, Lanaspá M, Pou L, Rosello E, et al. Voriconazole drug monitoring in the management of invasive fungal infection in immunocompromised children: a prospective study. *J Antimicrob Chemother* 2012;67:700–6.
- [688] Bartelink IH, Wolfs T, Jonker M, de Waal M, Egberts TC, Ververs TT, et al. Highly variable plasma concentrations of voriconazole in pediatric hematopoietic stem cell transplantation patients. *Antimicrob Agents Chemother* 2013;57:235–40.
- [689] Kotwani RN, Gokhale PC, Bodhe PV, Kirodian BG, Kshirsagar NA, Pandya SK. A comparative study of plasma concentrations of liposomal amphotericin B (L-AMP-LRC-1) in adults, children and neonates. *Int J Pharm* 2002;238:11–5.
- [690] Bochennek K, Tramsen L, Schedler N, Becker M, Klingebiel T, Groll AH, et al. Liposomal amphotericin B twice weekly as antifungal prophylaxis in paediatric haematological malignancy patients. *Clin Microbiol Infect* 2011;17:1868–74.
- [691] Groll AH, Silling G, Young C, Schwerdtfeger R, Ostermann H, Heinz W, et al. Randomized comparison of safety and pharmacokinetics of caspofungin, liposomal amphotericin B, and the combination of both in allogeneic hematopoietic stem cell recipients. *Antimicrob Agents Chemother* 2010;54:4143–9.
- [692] Sunakawa K, Tsukimoto I, Tsunematsu Y, Honda M, Iwai N, Maniwa T, et al. Evaluation of the safety and efficacy of liposomal amphotericin B (L-AMB) in children. *J Infect Chemother* 2012;18:456–65.
- [693] Walsh TJ, Adamson PC, Seibel NL, Flynn PM, Neely MN, Schwartz C, et al. Pharmacokinetics, safety, and tolerability of caspofungin in children and adolescents. *Antimicrob Agents Chemother* 2005;49:4536–45.
- [694] Neely M, Jafri HS, Seibel N, Knapp K, Adamson PC, Bradshaw SK, et al. Pharmacokinetics and safety of caspofungin in older infants and toddlers. *Antimicrob Agents Chemother* 2009;53:1450–6.
- [695] Cesaro S, Giacchino M, Locatelli F, Spiller M, Buldini B, Castellini C, et al. Safety and efficacy of a caspofungin-based combination therapy for treatment of proven or probable aspergillosis in pediatric hematological patients. *BMC Infect Dis* 2007;7:28.
- [696] Zoutis T, Lehrnbecher T, Groll AH, Steinbach WJ, Jafri HS, Maertens J, et al. Safety experience with caspofungin in pediatric patients. *Pediatr Infect Dis J* 2009;28:1132–5.
- [697] Zoutis TE, Jafri HS, Huang LM, Locatelli F, Barzilay A, Ebell W, et al. A prospective, multicenter study of caspofungin for the treatment of documented *Candida* or *Aspergillus* infections in pediatric patients. *Pediatrics* 2009;123:877–84.
- [698] Ngai AL, Bourque MR, Lupinacci RJ, Strohmaier KM, Kartsonis NA. Overview of safety experience with caspofungin in clinical trials conducted over the first 15 years: a brief report. *Int J Antimicrob Agents* 2011;38:540–4.
- [699] Manzoni P, Rizzollo S, Farina D. Response to "is liposomal amphotericin B really safety in neonates?". *Early Hum Dev* 2013;89:37.
- [700] Karadag-Oncel E, Ozsurekci Y, Yurdakok M, Kara A. Is liposomal amphotericin B really safety in neonates? *Early Hum Dev* 2013;89:35–6.
- [701] Scarcella A, Pasquariello MB, Giugliano B, Vendemmia M, de Lucia A. Liposomal amphotericin B treatment for neonatal fungal infections. *Pediatr Infect Dis J* 1998;17:146–8.
- [702] Juster-Reicher A, Flidel-Rimon O, Amitay M, Even-Tov S, Shinwell E, Leibovitz E. High-dose liposomal amphotericin B in the therapy of systemic candidiasis in neonates. *Eur J Clin Microbiol Infect Dis* 2003;22:603–7.
- [703] Cordonnier C, Rovira M, Maertens J, Olavarria E, Faucher C, Bilger K, et al. Voriconazole for secondary prophylaxis of invasive fungal infections in allogeneic stem cell transplant recipients: results of the VOSIFI study. *Haematologica* 2010;95:1762–8.
- [704] Liu F, Wu T, Wang JB, Cao XY, Yin YM, Zhao YL, et al. Risk factors for recurrence of invasive fungal infection during secondary antifungal prophylaxis in allogeneic hematopoietic stem cell transplant recipients. *Transpl Infect Dis* 2013;15:243–50.
- [705] Gerlach S, Vehreschild JJ, Ruping MJTG, Fischer G, Cornely OA. Epidemiology of *Aspergillus* spp. At the university hospital of cologne: molecular typing of environmental and clinical isolates. In: *Gemeinsame Jahrestagung der Deutschen, Österreichischen und Schweizerischen GHÖ*. Wien, Österreich: Onkologie; 2008.
- [706] Allinson K, Kolve H, Gumbinger HG, Vormoor HJ, Ehlert K, Groll AH. Secondary antifungal prophylaxis in paediatric allogeneic haematopoietic stem cell recipients. *J Antimicrob Chemother* 2008;61:734–42.
- [707] de Fabritiis P, Spagnoli A, Di Bartolomeo P, Locasciulli A, Cudillo L, Milone G, et al. Efficacy of caspofungin as secondary prophylaxis in patients undergoing allogeneic stem cell transplantation with prior pulmonary and/or systemic fungal infection. *Bone Marrow Transpl* 2007;40:245–9.
- [708] Martino R, Parody R, Fukuda T, Maertens J, Theunissen K, Ho A, et al. Impact of the intensity of the pretransplantation conditioning regimen in patients with prior invasive aspergillosis undergoing allogeneic hematopoietic stem cell transplantation: a retrospective survey of the infectious diseases working party of the European group for blood and marrow transplantation. *Blood* 2006;108:2928–36.
- [709] Kruger WH, Russmann B, de Wit M, Kroger N, Renges H, Sobottka I, et al. Haemopoietic cell transplantation of patients with a history of deep or invasive fungal infection during prophylaxis with liposomal amphotericin B. *Acta Haematol* 2005;113:104–8.

- [710] Nosari A, Ravini M, Cairoli R, Cozzi P, Marbello L, Marengo P, et al. Surgical resection of persistent pulmonary fungus nodules and secondary prophylaxis are effective in preventing fungal relapse in patients receiving chemotherapy or bone marrow transplantation for leukemia. *Bone Marrow Transpl* 2007;39:631–5.
- [711] Eliashar R, Resnick IB, Goldfarb A, Wohlgeleinter J, Gross M. Endoscopic surgery for sinonasal invasive aspergillosis in bone marrow transplantation patients. *Laryngoscope* 2007;117:78–81.
- [712] Cesaro S, Cecchetto G, De Corti F, Doderio P, Giacchino M, Caviglia I, et al. Results of a multicenter retrospective study of a combined medical and surgical approach to pulmonary aspergillosis in pediatric neutropenic patients. *Pediatr Blood Cancer* 2007;49:909–13.
- [713] Matt P, Bernet F, Habicht J, Gambazzi F, Gratwohl A, Zerkowski HR, et al. Predicting outcome after lung resection for invasive pulmonary aspergillosis in patients with neutropenia. *Chest* 2004;126:1783–8.
- [714] Reichenberger F, Habicht J, Kaim A, Dalquen P, Bernet F, Schlapfer R, et al. Lung resection for invasive pulmonary aspergillosis in neutropenic patients with hematologic diseases. *Am J Respir Crit Care Med* 1998;158:885–90.
- [715] Marr KA, Boeckh M, Carter RA, Kim HW, Corey L. Combination antifungal therapy for invasive aspergillosis. *Clin Infect Dis* 2004;39:797–802.
- [716] Perfect JR, Marr KA, Walsh TJ, Greenberg RN, DuPont B, de la Torre-Cisneros J, et al. Voriconazole treatment for less-common, emerging, or refractory fungal infections. *Clin Infect Dis* 2003;36:1122–31.
- [717] Candoni A, Mestroni R, Damiani D, Tiribelli M, Michelutti A, Silvestri F, et al. Caspofungin as first line therapy of pulmonary invasive fungal infections in 32 immunocompromised patients with hematologic malignancies. *Eur J Haematol* 2005;75:227–33.
- [718] Ng TT, Denning DW. Liposomal amphotericin B (ambisome) therapy in invasive fungal infections. Evaluation of United Kingdom compassionate use data. *Arch Intern Med* 1995;155:1093–8.
- [719] Hachem RY, Boktour MR, Hanna HA, Husni RN, Torres HA, Afif C, et al. Amphotericin B lipid complex versus liposomal amphotericin B monotherapy for invasive aspergillosis in patients with hematologic malignancy. *Cancer* 2008;112:1282–7.
- [720] Walsh TJ, Hiemenz JW, Seibel NL, Perfect JR, Horwith G, Lee L, et al. Amphotericin B lipid complex for invasive fungal infections: analysis of safety and efficacy in 556 cases. *Clin Infect Dis* 1998;26:1383–96.
- [721] Oppenheim BA, Herbrecht R, Kusne S. The safety and efficacy of amphotericin B colloidal dispersion in the treatment of invasive mycoses. *Clin Infect Dis* 1995;21:1145–53.
- [722] Herbrecht R, Letscher V, Andres E, Cavalier A. Safety and efficacy of amphotericin B colloidal dispersion. An overview. *Chemotherapy* 1999;45(Suppl. 1):67–76.
- [723] Betts R, Glasmacher A, Maertens J, Maschmeyer G, Vazquez JA, Teppler H, et al. Efficacy of caspofungin against invasive candida or invasive *Aspergillus* infections in neutropenic patients. *Cancer* 2006;106:466–73.
- [724] Egerer G, Reichert D, Pletz MW, Kaskel P, Krobot KJ, Maertens J. Caspofungin for treatment of invasive aspergillosis in Germany: results of a pre-planned subanalysis of an international registry. *Eur J Med Res* 2012;17:7.
- [725] Hiemenz JW, Raad II, Maertens JA, Hachem RY, Saah AJ, Sable CA, et al. Efficacy of caspofungin as salvage therapy for invasive aspergillosis compared to standard therapy in a historical cohort. *Eur J Clin Microbiol Infect Dis* 2010;29:1387–94.
- [726] Kartsonis NA, Saah AJ, Joy Lipka C, Taylor AF, Sable CA. Salvage therapy with caspofungin for invasive aspergillosis: results from the caspofungin compassionate use study. *J Infect* 2005;50:196–205.
- [727] Morrissey CO, Slavin MA, O'Reilly MA, Daffy JR, Seymour JF, Schwarzer AP, et al. Caspofungin as salvage monotherapy for invasive aspergillosis in patients with hematological malignancies or following allogeneic stem cell transplantation: efficacy and concomitant cyclosporin A. *Mycoses* 2007;50(Suppl. 1):24–37.
- [728] Leon-Gil C, Ubeda-Iglesias A, Loza-Vazquez A, de la Torre MV, Raurich-Puigdevall JM, Alvarez-Sanchez B, et al. Efficacy and safety of caspofungin in critically ill patients. *Procas study*. *Rev Esp Quimioter* 2012;25:274–82.
- [729] Enoch DA, Idris SF, Aliyu SH, Micallef C, Sule O, Karas JA. Micafungin for the treatment of invasive aspergillosis. *J Infect* 2014;68:507–26.
- [730] Hachem RY, Langston AA, Graybill JR, Perfect JR, Pedicone LD, Patino H, et al. Posaconazole as salvage treatment of invasive fungal infections in patients with underlying renal impairment. *J Antimicrob Chemother* 2008;62:1386–91.
- [731] Heinz WJ, Egerer G, Lellek H, Boehme A, Greiner J. Posaconazole after previous antifungal therapy with voriconazole for therapy of invasive aspergillus disease, a retrospective analysis. *Mycoses* 2013;56:304–10.
- [732] Caillot D. Intravenous itraconazole followed by oral itraconazole for the treatment of amphotericin-B-refractory invasive pulmonary aspergillosis. *Acta Haematol* 2003;109:111–8.
- [733] Chakrabarti A, Sethi S, Raman DS, Behera D. Eight-year study of allergic bronchopulmonary aspergillosis in an Indian teaching hospital. *Mycoses* 2002;45:295–9.
- [734] Tashiro T, Izumikawa K, Tashiro M, Morinaga Y, Nakamura S, Imamura Y, et al. A case series of chronic necrotizing pulmonary aspergillosis and a new proposal. *Jpn J Infect Dis* 2013;66:312–6.
- [735] Dupont B. Itraconazole therapy in aspergillosis: study in 49 patients. *J Am Acad Dermatol* 1990;23:607–14.
- [736] Sambatakou H, Dupont B, Lode H, Denning DW. Voriconazole treatment for subacute invasive and chronic pulmonary aspergillosis. *Am J Med* 2006;119:527 e517–524.
- [737] Saito T, Fujiuchi S, Tao Y, Sasaki Y, Ogawa K, Suzuki K, et al. Efficacy and safety of voriconazole in the treatment of chronic pulmonary aspergillosis: experience in Japan. *Infection* 2012;40:661–7.
- [738] Felton TW, Baxter C, Moore CB, Roberts SA, Hope WW, Denning DW. Efficacy and safety of posaconazole for chronic pulmonary aspergillosis. *Clin Infect Dis* 2010;51:1383–91.